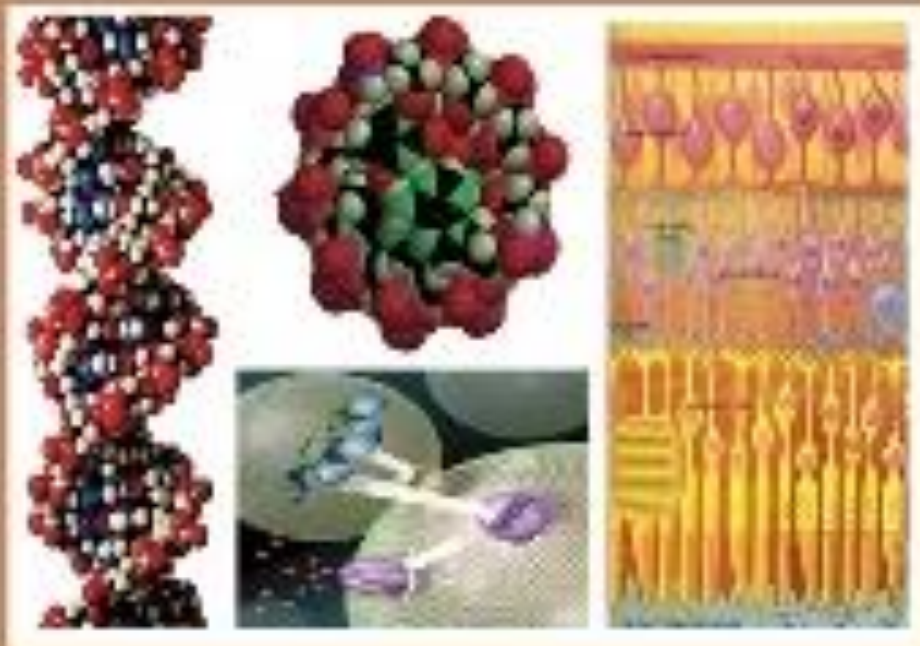




C

EGYPTIAN ACADEMIC JOURNAL OF
BIOLOGICAL SCIENCES


PHYSIOLOGY & MOLECULAR BIOLOGY



ISSN
2090-0767

WWW.EAJBS.ORG.ET

Vol. 16 No. 1 (2024)



Prophylactic Effect of Curcumin Against Long-Term and High-Dose Tartrazine-Induced Structural, Biochemical, and Genetic Alteration in Male Rats

Laila I. M. Ibrahim¹, Marwa S. M. Diab¹ and Samar H. K. Mohamed^{2*}

¹Molecular Drug Evaluation Department, Egyptian Drug Authority (National Organization for Drug Control and Research formerly), Giza, Egypt.

²Biotechnology Department, Faculty of Applied Health Sciences Technology, October 6 University, Giza, Egypt.

*E-mail: samar_kassem_moham@hotmail.com; DRSamarkassem.ams@o6u.edu.eg

ARTICLE INFO

Article History

Received:9/3/2024

Accepted:16/5/2024

Available:20/4/2024

Keywords:

Tartrazine;
Curcumin;
Antioxidants;
Genotoxicity;
Histopathology.

ABSTRACT

Background: Food coloring agents used in food remain controversial because many adverse effects are encountered. Therefore, the objective of the present study was to investigate whether curcumin has potential protection against oxidative stress, organ damage, and genotoxic effects induced by different doses of tartrazine, a synthetic food coloring agent, in male rats. **Experimental procedure:** Six groups were established as follows: Group 1 represented the control. Groups 2 and 3 were given tartrazine orally, with a daily dosage of 10 and 20 mg/kg b.w., respectively. Group 4 was given orally a daily dose of 50 mg curcumin/kg b.wt. Groups 5 and 6 were orally given daily doses of 10 and 20 mg/kg tartrazine and co-treated with 50 mg/kg curcumin, respectively. **Results:** The administration of low and high dose tartrazine for 30 and 60 days significantly increased the following parameters in proportion to the dose and time of exposure: body weight; levels of AST, ALT, urea, creatinine, reactive oxygen species, and lipid peroxidation; and reduced organ weight (liver, kidneys, and testes), concentrations of total protein, albumin, catalase (CAT), glutathione peroxidase (GPx), superoxide dismutase (SOD), free and total testosterone, sperm count, motility, and viability. Furthermore, tartrazine induced histopathological alterations and DNA damage in hepatic, renal and testicular tissues. Co-treatment of rats with curcumin and tartrazine revealed milder pathological alterations compared to rats treated with tartrazine alone. **Conclusion:** Taken together, this study showed that curcumin ameliorated the tartrazine-induced toxicity in the liver, kidney, and testis of male rats.

INTRODUCTION

Food additives are incorporated into basic food products to enhance their sensory properties, such as taste, appearance, texture, color, and preservation (Himri *et al.*, 2011). Based on the purpose of use, they can be grouped into five main categories commonly found in the modern food supply (Amin and Al-Shehri. 2018). Specifically, colouring compounds that give food vivid hues fall within one of these categories. Tartrazine (Tar) is a well-known food additive widely used as a coloring substance in the Egyptian food industry. Additionally, as a lemon-yellow substance, it serves as a saffron substitute in many developing nations as a cooking ingredient (Amin *et al.*, 2010). Tartrazine, recognized as FD, E102, and C Yellow 5, is a synthetically produced azo dye that is extracted from coal tar (Mehedi *et al.*, 2009). For humans, Tar's acceptable daily intake (ADI) should not exceed 7.5 mg/kg b.w.

The Food and Agriculture Organization and World Health Organization (JECFA) highly advise governments to monitor food additives misuse or if their overall intake exceeds the permissible level (FAO/WHO, 1999). Numerous studies have reported the widespread and unregulated use of such dyes in children's foods (Rahnama *et al.*, 2022). Juices and drinks, candy, potato chips, dressings, chocolates, ice cream, and jelly are just a few of the food products that may contain tartrazine (Ahmed *et al.*, 2021; Clemens *et al.*, 2023). Furthermore, tartrazine is commonly present in some medical preparations, including medicinal capsules and vitamins (Amin and Al-Shehri, 2018). To the best of our knowledge, no comprehensive studies to date about the analysis of synthetic food colourants in Egypt. In one Egyptian study, Tar was detected in soft drinks and jelly powders measuring 0.2-15 µg/ml and 25-125 µg/g, respectively (Abdel-Moemin, 2016). Many food additives are considered xenobiotics that humans are exposed to (Murray *et al.*, 2009) and overconsumption of these chemicals in food products can result in toxicity to humans (Al-Shinnawy 2008). Xenobiotics may elicit diverse biological effects, including pharmacological, toxic, and immunological reactions and cancer (Murray *et al.*, 2009). Variables, such as age, sex, nutritional status, and genetic makeup, may influence individual responses. The dose concentration and exposure frequency are critical factors determining diverse biological responses (Amin *et al.*, 2010). An extensive body of research has accumulated, revealing tartrazine's potential hazards (Kamal and Fawzia, 2018). Previous studies show that tartrazine induces allergic reactions in sensitive people (Nabila *et al.*, 2013) and may induce negative impacts in animals, such as kidney, liver, and testes toxicities and inflammation in the stomach lining (Moutinho *et al.*, 2007). Elevated eosinophil and lymphocyte counts were observed when rats were consumed for extended periods (Al-Seeni *et al.*, 2018). According to Mahfouz (2013), tartrazine is linked to a number of

immunologic reactions, including heat waves, migraines, anxiety, neurobehavioral toxicity, general weakness, itching, impaired vision, clinical depression, and purple skin patches. Numerous investigations have confirmed the mutagenic tartrazine effects in animal models (Sasaki *et al.*, 2002; Amin and Al-Shehri, 2018; Dos Santos *et al.*, 2022).

Natural colours derived from plant sources have become highly demanded in the food industry as safe ingredient alternatives for several synthetic colour additives that negatively impact health. Among the herbal resources identified was curcumin, a yellow polyphenol substance that is produced from turmeric (*Curcuma longa* L.) rhizomes (Indira Priyadarsini, 2013). It is commonly employed for food coloring (Govindarajan, 1980). Moreover, curcumin's activity is augmented by the methoxy groups present on the phenyl ring (Indira Priyadarsini, 2013). Curcumin also possesses antiviral and anti-inflammatory potential. It has also been demonstrated to be a potent scavenger of ROS in various disorders, thereby protecting crucial cellular components like DNA, proteins, and lipids (El-Wakf and El-Kholy, 2011). Furthermore, an anticancer effect of curcumin has been shown (Siddiqui *et al.*, 2018). Curcumin demonstrated modulatory effects on various genes involved in the pathogenesis of different diseases (Rahmani *et al.*, 2018). Several of these actions account for curcumin's potential to safeguard DNA from the destruction caused by free radicals and protect hepatocytes from toxins (Caglayan *et al.*, 2018). This study was conducted to investigate the possible role of curcumin as a natural coloring product in alleviating oxidative stress caused by low and high-dose tartrazine administration for 60 days. The curcumin-protecting effects on tartrazine induced structural, biochemical and genetic damage in the liver, kidney, and testes will be assessed.

MATERIALS AND METHODS

Food Colors Additives:

Tartrazine yellow 700 E102 was acquired from a local provider and mixed

with the diet and drinking water of male albino rats. Tartrazine was given orally following the technique outlined by Walton *et al.* (1999).

Experimental Animals:

Adult male Sprague-Dawley white albino rats weighing 180–210 g were acquired from the animal house of the Egyptian Drug Authority (formerly NODCAR), Egypt. They were kept in a laboratory room that was adequately ventilated and maintained under controlled conditions. A 25°C room temperature was maintained, and the rats were subjected to a 12-hour dark/12-hour light cycle with appropriate humidity levels. The animals were placed in plastic cages maintained within hygienic circumstances and given ad libitum access to standard rat chow pellets and tap water for drinking. The animals were treated with care and respect during the experiment. Animal procedures adhered to the guidelines recommended by the Canadian Committee for Care and agreed via the Institutional Animal Ethics Committee of the Egyptian Drug Authority and October 6 University. The ethical approval number for experimental study provided by October 6 University is: 20230710.

Experimental Design:

The rats received a nutritionally adequate standard laboratory diet ad libitum for 60 days. Afterward, they were allocated into 6 groups randomly, each with 10 rats: group 1 corresponded to the controls and was given distilled water, and groups 2 and 3 were given 10 and 20 mg of tartrazine /kg BW/day diluted in distilled water, respectively, group 4 received 50 mg curcumin /kg BW/day), groups 5 and 6 received 10 and 20 mg tartrazine with 50 mg curcumin /kg BW/day, respectively. Tartrazine and curcumin were administered daily by oral gavage for 60 days. First, blood samples were taken after 30 days. Second, after the experiment was completed (60 days), the rats were fasted overnight, except for water. Blood samples were obtained from the jugular veins under anesthesia in glass tubes deprived of anticoagulant to obtain serum. The blood samples were allowed to coagulate at room

temperature and then underwent centrifugation for 10 min at 3000 rpm, and the resulting serum was kept at -80 °C till further use. Serum samples were used to determine the following parameters: AST, ALT, total proteins, urea, creatinine and testosterone (free and total).

Histopathologic Examination:

During autopsy, tissue specimens were acquired from the liver, kidneys, and testes of various rat groups. These specimens were then washed and divided into three parts; one part for storage at 80 °C for further investigation, another part was homogenized in homogenizing buffer solution and the last part was preserved in a 10% saline formalin solution for 24 hours. After washing with tap water, the tissue samples underwent dehydration utilizing a series of alcohol dilutions, including ethyl, methyl, and absolute ethyl alcohol. Following xylene clearing, the samples were paraffinized and placed in a hot-air oven (56°C) for 24 h. The tissue samples were embedded in paraffin wax and sectioned using a sledge microtome to produce 4-micron-thick tissue sections. These sections were carefully positioned on glass slides and subjected to deparaffinization and staining with hematoxylin and eosin for inspection using a light microscope (Drury 1983).

Determination of Aspartate Aminotransferases (AST) activity:

The calorimetric estimation of aspartate aminotransferase (AST) and alanine aminotransferase (ALT) activities followed the technique given by Reitman and Frankel (1957), using kits purchased from QCA, Apdo, Spain.

Determination of Plasma Blood Urea:

Enzymatic colorimetric evaluation of urea was accomplished following the Fawcett and Soctt (1960) technique using kits provided by protein using Bio-diagnostic kits, Giza, Egypt.

Determination of Plasma Blood Creatinine:

Kinetic determination of creatinine was accomplished by applying the procedure of Bartels *et al.* (1972) using Bio-diagnostic kits, in Giza, Egypt. In this method, the

creatinine is mixed with picrate in an alkaline solution, forming a colored complex. This color complex's intensity can then be measured at 546 nm in a spectrophotometer.

Determination of Catalase (CAT) Activity:

Catalase was carried out utilizing the procedure of Aebi (1984), and its tissue activity was presented as the amount of H₂O₂ utilized/min/mg protein using Bio-diagnostic kits (Giza, Egypt).

Determination of Superoxide Dismutase (SOD) Activity:

SOD activity determination in tissue homogenates was achieved following the kinetic procedure described by Marklund and Marklund (1974) using Bio-diagnostic kits, in Giza, Egypt.

Determination of Lipid Peroxidation:

The level of lipid peroxide formation in tissue homogenates was assessed by measuring thiobarbituric acid reactive substances (TBARS), utilizing the procedure outlined by Uchiyama and Mihara (1978) using Bio-diagnostic kits, Giza, Egypt.

Determination of Total Proteins:

Total protein levels were determined in the serum following the technique of Gornall *et al.* (1949) and using Bio-diagnostic kits, in Giza, Egypt.

Quantification of Reactive Oxygen Species (ROS) Content:

The ROS production was quantified in tissue homogenate by utilizing a variation of an established assay that measures the transformation of nitro blue tetrazolium (NBT) to formazan inside the cell due to the presence of superoxide anions (Vrablic *et al.*, 2001) using Bio-diagnostic kits, Giza, Egypt.

Determination of Testosterone Total And Free:

Serum testosterone levels were estimated using kits provided from Monocent, CA, USA

Measurement of Sperm Motility And Viability:

The evaluation of sperm progressive motility and viability was conducted under a microscope within 2-4 minutes of isolation from the cauda epididymis using the protocol previously described by Sonmez *et al.* (2005).

To obtain the required fluid, a pipette was utilized to extract fluid from the cauda epididymis, which was then mixed with Tris buffer solution to make a 2 ml solution. The motility of the sperm was assessed at a magnification of 9400, and the motile sperm percentage was estimated.

Comet Assay To Identify DNA Damage In Hepatic, Kidney, and Testes Tissue:

DNA damaging analysis was achieved utilizing the comet assay (single-cell gel electrophoresis) (Himri *et al.*, 2012). Samples of liver weighing 100 mg were obtained from all experimental groups and minced in a chilled homogenizing buffer solution comprising 0.075 M NaCl and 0.024 M Na₂EDTA. The minced samples were gently homogenized on ice using a homogenizer (Ikemoto Scientific Technology Company Ltd., Japan). The resulting cell suspension underwent centrifuging 700X g for 10 minutes at 4 °C and was then re-suspended within a cold buffer. The slide visualization was conducted utilizing an epifluorescence microscope. The genotoxicity-induced DNA migration length (comet tail length) was determined by scanning digital images of the samples using an image analyzer software (Comet V image analyzer) (Gyori *et al.*, 2014). Additionally, approximately 505 randomly selected cells from each sample were observed to obtain additional measurements, including the tail length (TL), DNA tail intensity (TI), and DNA tail moment (TM). TL is the distance between the final signal in the tail and the comet head, while TI is calculated by dividing the amount of DNA in the tail by the DNA in the nucleus and multiplying it by 100. TM accounts for the product of the DNA amount in the tail and TL. All assays have been repeated three times and compared with the control group to ensure the accuracy and reliability of the results.

Histopathology:

Autopsy samples were collected from rats' liver, kidneys, and testes in various experimental groups and fixed in 10% formol saline for a day. After being washed with tap water, the specimens underwent a

dehydration process using a series of alcohol percentage solutions, including ethyl alcohol, and absolute ethyl alcohol. Once dehydration was complete, the specimens were cleared using xylene and then embedded in paraffin for 24 hours in a hot air oven at 56 degrees. The paraffin-embedded tissue blocks were prepared for sectioning at a thickness of 4 microns utilizing a sledge microtome. After collection onto glass slides, the tissue sections underwent deparaffinization, followed by staining with hematoxylin and eosin stain, allowing examination through a light electric microscope (Drury 1983).

Statistical Analysis:

The mean values \pm SE were used to present the collected data, and statistical analysis was conducted utilizing one-way ANOVA to determine the variation difference in measured indices among experimental groups followed by student's t-test. The statistical significance was determined using a criterion of $p < 0.05$ for the biochemical data. The statistical analysis was accomplished utilizing the SPSS statistical

version 21 software package (SPSS® Inc., USA).

RESULTS

Ameliorative effect of curcumin on liver, kidney, testes weights, and body weight in rats given tartrazine.

According to the data presented in Table 1, the administration of tartrazine (high and low doses) induced a significant reduction ($P < 0.05$) in the weight of the liver, kidneys, and testes relative to the control group. Additionally, a significant increase ($P < 0.05$) in body weight was observed in the groups treated with tartrazine. Conversely, groups that received 10 and 20 mg/kg tartrazine (TAR) and 50 mg/kg curcumin (CUR) simultaneously showed ameliorative consequences on body weight and organ weights in comparison with the group that received 10 and 20 mg/kg tartrazine (TAR) respectively. Moreover, no considerable impact was recognized in the groups that received both tartrazine (10 and 20 mg/kg) and curcumin (50 mg/kg) relative to the control group.

Table 1: Effect of curcumin (50 mg/kg) on organ weights and body weights in rats fed with tartrazine (10 and 20 mg/kg) for 60 days.

Groups	Organ weights (g)			Body weight (g)
	Liver (g)	Kidneys (g)	Testis (g)	
Control	6.85 \pm 0.10 ^a	1.63 \pm 0.58 ^a	2.63 \pm 0.32 ^a	261 \pm 1.23 ^a
10 mg/kg TAR	5.10 \pm 0.09 ^d	1.50 \pm 0.38 ^d	2.41 \pm 0.15 ^d	291 \pm 1.42 ^d
20 mg/kg TAR	4.82 \pm 0.11 ^e	1.11 \pm 0.29 ^e	2.10 \pm 0.22 ^e	325 \pm 1.19 ^e
50 mg/kg CUR	6.83 \pm 0.23 ^a	1.65 \pm 0.32 ^a	2.61 \pm 0.41 ^a	265 \pm 1.33 ^a
10 mg TAR + 50 mg CUR/kg	6.00 \pm 0.17 ^b	1.54 \pm 0.27 ^b	2.50 \pm 0.19 ^b	285 \pm 1.15 ^b
20 mg TAR + 50 CUR mg/kg	5.61 \pm 0.10 ^c	1.48 \pm 0.25 ^c	2.38 \pm 0.32 ^c	298 \pm 1.42 ^c

Values represent the mean \pm SE of 10 rats. Values labeled with similar letters revealed no significant differences at $P \leq 0.05$. Values within a column that do not share the same superscripted letters significantly differ at $P < 0.05$.

The Role of Curcumin on Biochemical Parameters Altered by Tartrazine Toxicity in Male Albino Rats.

The curcumin protective effects on oxidative stress induced by tartrazine within male rats are provided in Table 2. The findings demonstrated substantial improvement in serum AST and ALT

activities in groups that received 10 and 20 mg/kg tartrazine and 50 mg/kg curcumin after 30 and 60 days, respectively, compared to the tartrazine-treated group. The administration of 10 and 20 mg/kg tartrazine significantly increased AST and ALT activity after 30 and 60 days in comparison with the control group.

Table 2: Curcumin ameliorative effect on tartrazine-induced elevation of AST and ALT within male albino rats.

Groups	AST (U/L)		ALT (U/L)	
	30 days	60 days	30 days	60 days
Control	52.00 ± 1.25 ^a	54.61 ± 1.22 ^a	38.20 ± 0.91 ^a	40.60 ± 1.08 ^a
10 mg/kg TAR	61.60 ± 1.44 ^c	81.22 ± 2.51 ^c	48.92 ± 0.83 ^c	62.17 ± 0.89 ^c
20 mg/kg TAR	85.34 ± 1.18 ^e	125.00 ± 3.17 ^e	60.6 ± 1.01 ^e	85.00 ± 1.20 ^e
50 mg/kg CUR	52.30 ± 1.19 ^a	55.10 ± 1.38 ^a	37.14 ± 0.82 ^a	37.20 ± 0.50 ^a
10 mg TAR + 50 mg CUR/kg	57.40 ± 1.35 ^b	64.91 ± 1.30 ^b	40.62 ± 0.73 ^b	47.02 ± 1.08 ^b
20 mg TAR + 50 mg CUR/kg	72.36 ± 1.45 ^d	93.88 ± 1.80 ^d	51.83 ± 1.00 ^d	61.30 ± 1.16 ^d

Values represent the mean ± SE of 10 rats. Values labeled with similar letters revealed no significant differences at $P \leq 0.05$. Values within a column that do not share the same superscripted letters significantly differ at $P < 0.05$.

The data reported in Table 3, indicate an increasingly significant rise in serum urea and creatinine concentrations among rats administered 10 and 20 mg/kg of TAR, along with a considerable decline in serum albumin in comparison with the control groups. Alternatively, in the groups that

received both 10 and 20 mg/kg tartrazine and 50 mg/kg curcumin (CUR) simultaneously, there was a significant improvement in serum urea, creatinine, and albumin levels after 30 and 60 days compared to the groups treated with tartrazine alone.

Table 3 Curcumin ameliorative effect on the tartrazine-induced rise of creatinine and urea in male albino rats.

Groups	Urea (mg /dl)		Creatinine (mg /dl)		Albumin (g/L)	
	30 days	60 days	30 days	60 days	30 days	60 days
Control	30.00 ± 0.88 ^a	30.81 ± 0.90 ^a	0.63 ± 0.05 ^a	0.64 ± 0.03 ^a	5.41 ± 0.21 ^a	5.46 ± 0.19 ^a
10 mg/kg TAR	38.00 ± 0.57 ^c	53.90 ± 0.66 ^c	0.80 ± 0.31 ^c	1.09 ± 0.16 ^c	5.16 ± 0.16 ^c	4.80 ± 0.19 ^c
20 mg/kg TAR	58.50 ± 1.23 ^e	71.4 ± 0.86 ^e	1.4 ± 0.19 ^e	1.65 ± 0.13 ^e	4.30 ± 0.21 ^e	3.61 ± 0.25 ^e
50 mg/kg CUR	30.08 ± 0.41 ^a	28.9 ± 0.15 ^a	0.64 ± 0.23 ^a	0.61 ± 0.25 ^a	5.38 ± 0.16 ^a	5.50 ± 0.19 ^a
10 mg TAR + 50 mg CUR/kg	35.18 ± 0.29 ^b	40.80 ± 0.19 ^b	0.68 ± 0.023 ^b	0.71 ± 0.18 ^b	5.30 ± 0.13 ^b	5.19 ± 0.18 ^b
20 mg TAR + 50 mg CUR/kg	46.25 ± 0.32 ^d	50.00 ± 1.04 ^d	0.70 ± 0.23 ^d	0.89 ± 0.17 ^d	4.62 ± 0.15 ^d	4.69 ± 0.10 ^d

Values represent the mean ± SE of 10 rats. Values labeled with similar letters revealed no significant differences at $P \leq 0.05$. Values within a column that do not share the same superscripted letters significantly differ at $P < 0.05$.

The results showed amelioration in groups administered 50 mg/kg CUR combined with 10 and 20 mg/kg TAR after 30 and 60 days of testosterone (total and testosterone-free) in serum relative to the

control group. Furthermore, groups administered 10 and 20 mg/kg TAR alone exhibited the lowest free and total testosterone levels (Table 4).

Table 4 Curcumin ameliorative effect on the tartrazine-induced decrease of testosterone total and free in male albino rats.

Groups	Testosterone total (ng/ml)		Testosterone-free (ng/ml)	
	30 days	60 days	30 days	60 days
Control	4.00 ± 0.13 ^a	4.05 ± 0.28 ^a	1.36 ± 0.18 ^a	1.38 ± 0.09 ^a
10 mg/kg TAR	3.21 ± 0.17 ^c	2.41 ± 0.19 ^c	1.0 ± 0.13 ^c	0.71 ± 0.09 ^c
20 mg/kg TAR	1.80 ± 0.25 ^e	1.00 ± 0.13 ^e	0.62 ± 0.10 ^e	0.41 ± 0.02 ^e
50 mg/kg CUR	4.08 ± 0.23 ^a	4.10 ± 0.25 ^a	1.40 ± 0.21 ^a	1.50 ± 0.08 ^a
10 mg TAR + 50 CUR mg/kg	3.68 ± 0.15 ^a	2.80 ± 0.18 ^b	1.27 ± 0.14 ^b	1.10 ± 0.14 ^b
20 mg TAR + 50 CUR mg/kg	3.00 ± 0.21 ^d	0.80 ± 0.31 ^d	0.81 ± 0.20 ^d	0.77 ± 0.09 ^d

Values represent the mean ± SE of 10 rats. Values labeled with similar letters revealed no significant differences at $P \leq 0.05$. Values within a column that do not share the same superscripted letters significantly differ at $P < 0.05$.

Table 5, showed that administering 10 and 20 mg tartrazine/kg body weight/day considerably reduced sperm count, motility, and viability relative to the control. Administration of CUR in the group treated with 10 and 20 mg/kg TAR showed

ameliorative effects on sperm count, motility, and viability compared to the group that received TAR only. There was no discernible advantage for the curcumin group over the control group.

Table 5 Curcumin ameliorative effect on tartrazine-induced motility, vitality, and count of sperms in the semen of male albino rats (Mean ± SE).

Parameters	Treatment (60 days)					
	Control	10 mg/kg TAR	20 mg/kg TAR	50 mg/kg CUR	10 mg TAR + 50 mg CUR/kg	20 mg TAR + 50 mg CUR/kg
Sperm count (Million/cc)	3.85 ± 0.18 ^a	2.65 ± 0.17 ^c	1.8 ± 0.41 ^e	3.88 ± 0.27 ^a	3.65 ± 0.27 ^b	2.41 ± 0.27 ^d
Viability (%)	90 ± 0.24 ^a	65 ± 0.23 ^c	45 ± 0.51 ^e	91 ± 0.31 ^a	73 ± 0.31 ^b	61 ± 0.31 ^d
	Motility (%)					
Progressive:	80 ± 0.48 ^a	65 ± 0.44 ^c	38 ± 0.61 ^e	83 ± 0.38 ^a	70 ± 0.39 ^b	50 ± 0.21 ^d
Non-progressive:	20 ± 0.36 ^a	35 ± 0.29 ^c	62 ± 0.39 ^e	27 ± 0.15 ^a	30 ± 0.17 ^b	50 ± 0.19 ^d

Values represent the mean ± SE of 10 rats. Values labeled with similar letters revealed no significant differences at $P \leq 0.05$. Values within a column that do not share the same superscripted letters significantly differ at $P < 0.05$.

Effect of Curcumin on Tartrazine Induced-Oxidative Stress Parameters in Male Rat Tissue:

Table 6, demonstrates that the administration of TAR at 10 and 20 mg/kg had a discernible effect on the liver tissue, as evidenced by improved concentrations of reactive oxygen species (ROS) and lipid peroxidation (LPO), coupled with a reduction in the levels of catalase (CAT), superoxide dismutase (SOD), and glutathione peroxidase (GPx) relative to the control group. In contrast, groups treated with 10 and 20 mg/kg TAR plus 50 mg CUR showed ameliorative effects compared to groups that received only 10 and 20 mg/kg TAR. As shown in Table 6, the co-administration of CUR (50 mg/kg) with TAR (10 and 20 mg/kg) had an ameliorative effect on catalase (CAT),

glutathione peroxidase (GPx), lipid peroxidation (LPO), reactive oxygen species (ROS), and superoxide dismutase (SOD) in the kidneys of rats compared to groups treated with Tar alone. Alternatively, the groups that received 10 and 20 mg/kg TAR alone showed increased ROS and LPO and decreased GPx, CAT, and SOD relative to the control. Groups receiving 10 and 20 mg/kg TAR demonstrated significant increases in ROS and LPO and significant decreases in GPx, CAT, and SOD relative to the control. Alternatively, administering CUR at a dose of 50 mg/kg demonstrated a lowering effect on ROS and LPO levels in the testes of rats treated with tartrazine. Additionally, curcumin showed an increasing effect on GPx, CAT, and SOD levels (Table 6).

Table 6: Ameliorative effect of curcumin on tartrazine-induced oxidative stress in male rat liver, kidney and testes tissue homogenates after 60 days.

	Groups	ROS ($\mu\text{mol NBT/g}$ tissue)	MDA (nmol/mg protein)	GPx (IU/g protein)	CAT (min/mg-l protein)	SOD (min/mg protein)
Liver	Control	28.40 \pm 1.16 ^a	0.35 \pm 0.05 ^a	36.22 \pm 0.83 ^a	22.41 \pm 0.88 ^a	125.26 \pm 1.26 ^a
	10 mg/kg TAR	44.94 \pm 1.60 ^d	1.66 \pm 0.03 ^d	21.55 \pm 1.01 ^d	10.80 \pm 0.61 ^d	81.00 \pm 1.50 ^d
	20 mg/kg TAR	53.00 \pm 1.68 ^e	2.80 \pm 0.08 ^e	15.00 \pm 0.87 ^e	7.43 \pm 0.44 ^e	60.14 \pm 1.38 ^e
	50 mg/kg CUR	26.83 \pm 1.52 ^a	0.32 \pm 0.02 ^a	34.80 \pm 0.90 ^a	22.58 \pm 1.00 ^a	125.00 \pm 1.91 ^a
	10 mg/kg TAR + 50 mg/kg CUR	34.93 \pm 1.35 ^b	1.20 \pm 0.06 ^b	31.10 \pm 1.00 ^b	18.32 \pm 0.32 ^b	110.12 \pm 2.25 ^b
	20 mg/TAR + 50 mg CUR/kg	40.83 \pm 1.21 ^c	1.45 \pm 0.04 ^c	25.00 \pm 0.88 ^c	15.62 \pm 1.06 ^c	88.40 \pm 1.19 ^c
Kidney	Control	9.81 \pm 0.31 ^a	0.29 \pm 0.04 ^a	21.37 \pm 0.33 ^a	16.10 \pm 0.82 ^a	105.14 \pm 1.81 ^a
	10 mg/kg TAR	16.84 \pm 0.92 ^d	0.45 \pm 0.16 ^d	17.86 \pm 0.41 ^d	10.25 \pm 1.01 ^d	81.00 \pm 1.21 ^d
	20 mg/kg TAR	21.64 \pm 1.30 ^e	1.51 \pm 0.19 ^e	11.22 \pm 0.53 ^e	8.91 \pm 0.44 ^e	60.18 \pm 1.83 ^e
	50 mg/kg CUR	9.60 \pm 0.42 ^a	0.28 \pm 0.03 ^a	21.00 \pm 0.17 ^a	16.19 \pm 0.44 ^a	106.00 \pm 0.98 ^a
	10 mg/TAR + 50 mg CUR/kg	13.20 \pm 0.38 ^b	0.40 \pm 0.15 ^b	15.55 \pm 0.15 ^b	14.18 \pm 0.32 ^b	95.25 \pm 1.02 ^b
	20 mg/TAR + 50 mg CUR/kg	16.53 \pm 0.25 ^c	1.03 \pm 0.14 ^c	13.09 \pm 0.10 ^c	10.55 \pm 1.08 ^c	83.66 \pm 0.90 ^c
Testes	Control	8.92 \pm 0.42 ^a	0.52 \pm 0.28 ^a	14.72 \pm 0.62 ^a	17.25 \pm 0.91 ^a	117.55 \pm 0.54 ^a
	10 mg/kg TAR	12.25 \pm 0.31 ^d	1.06 \pm 0.21 ^d	11.42 \pm 0.31 ^d	14.30 \pm 0.38 ^d	90.55 \pm 1.86 ^d
	20 mg/kg TAR	18.65 \pm 0.83 ^e	1.76 \pm 0.62 ^e	8.72 \pm 0.58 ^e	11.25 \pm 0.69 ^e	65.22 \pm 1.38 ^e
	50 mg/kg CUR	8.86 \pm 0.62 ^a	0.50 \pm 0.27 ^a	14.23 \pm 0.89 ^a	17.20 \pm 0.88 ^a	116.92 \pm 1.65 ^a
	10 mg/TAR + 50 mg CUR/kg	9.18 \pm 0.40 ^b	0.65 \pm 0.12 ^b	12.02 \pm 0.69 ^b	15.61 \pm 0.89 ^b	99.65 \pm 1.43 ^b
	20 mg/TAR + 50 mg CUR/kg	12.61 \pm 0.48 ^c	0.98 \pm 0.25 ^c	10.03 \pm 0.82 ^c	13.82 \pm 0.55 ^c	86.44 \pm 0.41 ^c

Values represent the mean \pm SE of 10 rats. Values labeled with similar letters revealed no significant differences at $P \leq 0.05$. Values within a column that do not share the same superscripted letters significantly differ at $P < 0.05$.

Effect of Tartrazine on DNA Damage Markers:

DNA Fragmentation:

The extent of DNA damage in the liver of rats was determined utilizing a comet assay, and the findings were displayed in the Table and 7 Figure 1. This analysis aimed to inspect the consequence of tartrazine administration compared to the normal control. Tartrazine administration (10 and 20

mg/kg) for 60 days caused a considerable rise in DNA damage ($P < 0.05$), as revealed by the enlarged tail length, tail DNA percentage, and tail moment relative to the controls. In contrast, the groups that co-received tartrazine and curcumin (10 and 20 mg/kg TAR with 50 mg CUR) showed no substantial variance in DNA damage (tail length) compared to the healthy control.

Table 7: Ameliorative effect Curcumin on tartrazine-induced DNA damage in rat Liver.

Groups	DNA marker in the Liver				
	%	Tail Length	DNA in Tail	Tail moment	Olive moment
Control	10.80 \pm 0.61 ^a	6.82 \pm 0.43 ^a	5.24 \pm 0.32 ^a	0.35 \pm 0.03 ^a	0.30 \pm 0.05 ^a
10 mg/kg (TAR)	15.20 \pm 1.02 ^d	8.96 \pm 0.51 ^d	10.30 \pm 0.92 ^d	0.88 \pm 0.06 ^d	1.00 \pm 0.12 ^d
20 mg/kg (TAR)	19.60 \pm 0.86 ^e	12.60 \pm 1.21 ^e	15.10 \pm 0.65 ^e	1.35 \pm 0.13 ^e	2.01 \pm 0.10 ^e
50 mg/kg CUR	10.71 \pm 0.44 ^a	6.69 \pm 0.63 ^a	5.21 \pm 0.60 ^a	0.31 \pm 0.05 ^a	0.29 \pm 0.02 ^a
10 mg TAR + 50 mg CUR/kg	13.00 \pm 0.88 ^b	8.60 \pm 0.44 ^b	8.00 \pm 0.45 ^b	0.73 \pm 0.10 ^b	0.55 \pm 0.20 ^b
20 mg/TAR+ 50 mg CUR/kg	15.83 \pm 0.87 ^c	9.13 \pm 0.32 ^c	9.65 \pm 1.02 ^c	0.91 \pm 0.07 ^c	1.40 \pm 0.30 ^c

Values represent the mean \pm SE of 10 rats. Values labeled with similar letters revealed no significant differences at $P \leq 0.05$. Values within a column that do not share the same superscripted letters significantly differ at $P < 0.05$.

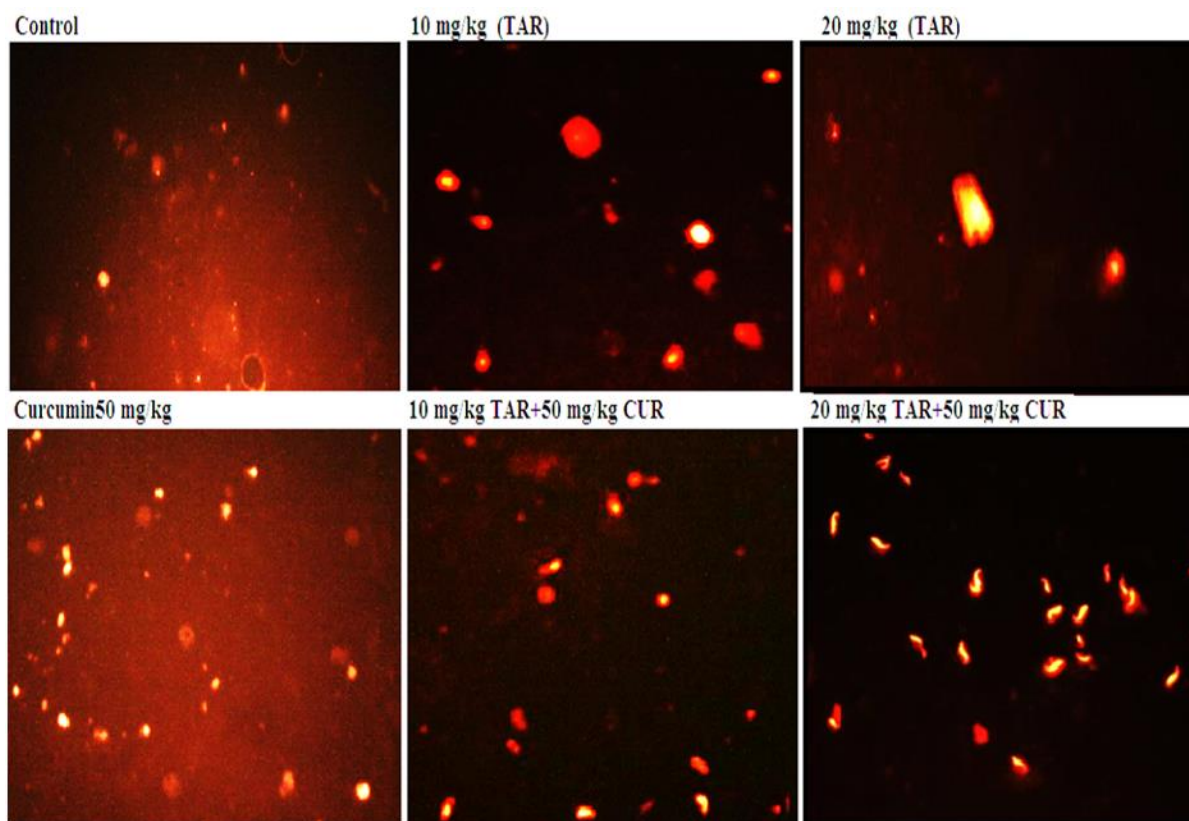


Fig. 1 :Comet assay for DNA damage in liver tissues from various groups. G1, control group; G2, 10 g/kg (TAR) group; G3, 20 mg/kg (TAR) group; G4, 50 mg (CUR) G5, 10 TAR+ 50 mg/kg CUR) group; G6, 20 TAR+ 50 mg/kg CUR group.

Figure 2, and Table 8, illustrate the findings of the comet assay conducted to determine the level of DNA damage in the kidneys of rats following exposure to tartrazine relative to the control. Tartrazine (10 and 20 mg/kg TAR) administration significantly increased DNA damage ($P <$

0.05) as indicated by the enlarged tail length, tail moment, and tail DNA% relative to the control. In contrast, in groups treated with tartrazine + curcumin (10 and 20 mg/kg TAR with 50 mg CUR), there was no substantial variance in DNA damage (tail length) compared to healthy controls.

Table 8 :Ameliorative effect of Curcumin on tartrazine-induced DNA damage in rat kidneys

Groups	DNA marker in kidney				
	%	Tail Length	DNA in Tail	Tail moment	Olive moment
Control	10.60 ± 0.59 ^a	6.10 ± 0.30 ^a	7.50 ± 0.65 ^a	0.55 ± 0.04 ^a	0.92 ± 0.17 ^a
10 mg/kg (TAR)	12.90 ± 1.04 ^d	8.34 ± 0.28 ^d	8.80 ± 0.44 ^d	0.81 ± 0.02 ^d	1.40 ± 0.20 ^d
20 mg/kg (TAR)	15.84 ± 1.09 ^e	10.80 ± 0.54 ^e	11.15 ± 0.83 ^e	1.08 ± 0.06 ^e	1.93 ± 0.19 ^e
50 mg/kg CUR	10.46 ± 0.82 ^a	6.05 ± 0.28 ^a	7.42 ± 0.39 ^a	0.54 ± 0.05 ^a	0.90 ± 0.10 ^a
20 mg/TAR+ 50 mg CUR/kg CUR/kg	11.00 ± 0.68 ^b	7.60 ± 0.43 ^b	7.81 ± 0.56 ^b	0.61 ± 0.10 ^b	1.08 ± 0.25 ^b
20 mg/TAR+ 50 mg CUR/kg	12.60 ± 0.79 ^c	8.82 ± 0.61 ^c	8.91 ± 1.04 ^c	0.83 ± 0.12 ^c	1.39 ± 0.38 ^c

Values represent the mean ± SE of 10 rats. Values labeled with similar letters revealed no significant differences at $P \leq 0.05$. Values within a column that do not share the same superscripted letters significantly differ at $P < 0.05$.

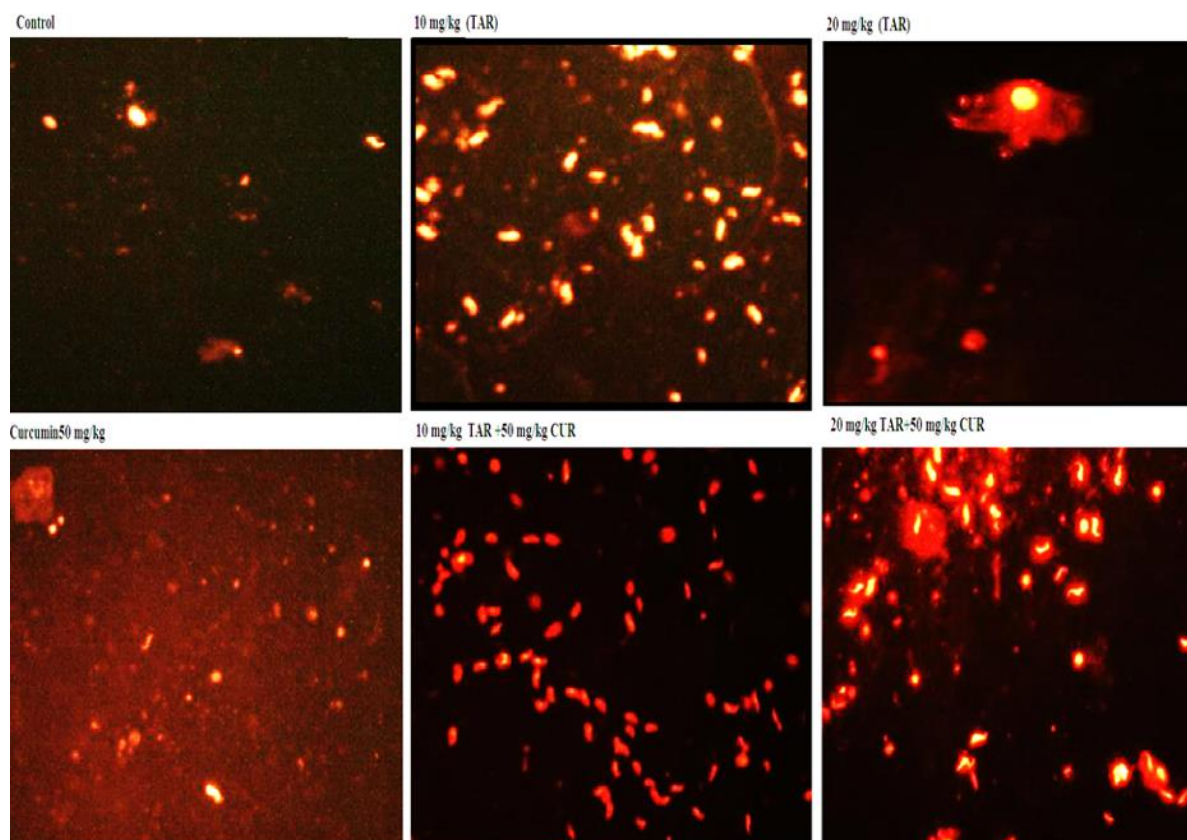


Fig. 2: Comet assay for DNA damage in kidney tissues from different groups Where G1, control group; G2, 10g/kg TAR group; G3, 20 mg/kg TAR group; G4, 50mg CUR; G5, 10 TAR+ 50mg/kg CUR group; G6, 20 TAR+ 50 CUR group.

The extent of DNA damage in the testes of rats was determined utilizing a comet assay, and the findings were displayed in the **Table 9** and **Figure 3**. This assay was carried out to inspect the consequence of tartrazine administration compared to the normal control. Tartrazine administration (10 and 20mg/kg TAR) significantly increased DNA

damage ($P < 0.05$), as inferred from the increased tail length, tail moment, and tail DNA% relative to the control. Alternatively, the groups that received tartrazine + curcumin (10 and 20 mg/kg TAR with 50 mg CUR) showed no substantial variance in DNA damage (tail length) compared to the healthy control.

Table 9: Ameliorative effect of curcumin on tartrazine-induced DNA damage in rat testes.

Groups	DNA marker in testes				
	%	Tail Length	DNA in Tail	Tail moment	Olive moment
Control	6.00 ± 0.90 ^a	10.06 ± 0.88 ^a	7.64 ± 0.68 ^a	0.64 ± 0.28 ^a	1.25 ± 0.22 ^a
10 mg/kg (TAR)	9.90 ± 1.06 ^d	12.63 ± 1.04 ^d	9.92 ± 0.91 ^d	1.14 ± 0.05 ^d	1.42 ± 0.38 ^d
20 mg/kg (TAR)	15.80 ± 1.43 ^e	14.25 ± 1.22 ^e	11.34 ± 0.64 ^e	1.92 ± 0.17 ^e	2.15 ± 0.25 ^e
50 mg/kg CUR	5.92 ± 0.66 ^a	10.01 ± 1.09 ^a	7.52 ± 0.61 ^a	0.63 ± 0.06 ^a	1.18 ± 0.40 ^a
10 mg TAR + 50 mg CUR/kg	7.50 ± 0.13 ^b	12.0 ± 0.62 ^b	8.17 ± 0.55 ^b	0.70 ± 0.14 ^b	1.06 ± 0.35 ^b
20 mg/TAR+ 50 mg CUR/kg	10.20 ± 0.92 ^c	12.61 ± 0.58 ^c	8.98 ± 0.29 ^c	1.20 ± 0.41 ^c	1.38 ± 0.45 ^c

Values represent the mean ± SE of 10 rats. Values labeled with similar letters revealed no significant differences at $P \leq 0.05$. Values within a column that do not share the same superscripted letters significantly differ at $P < 0.05$.

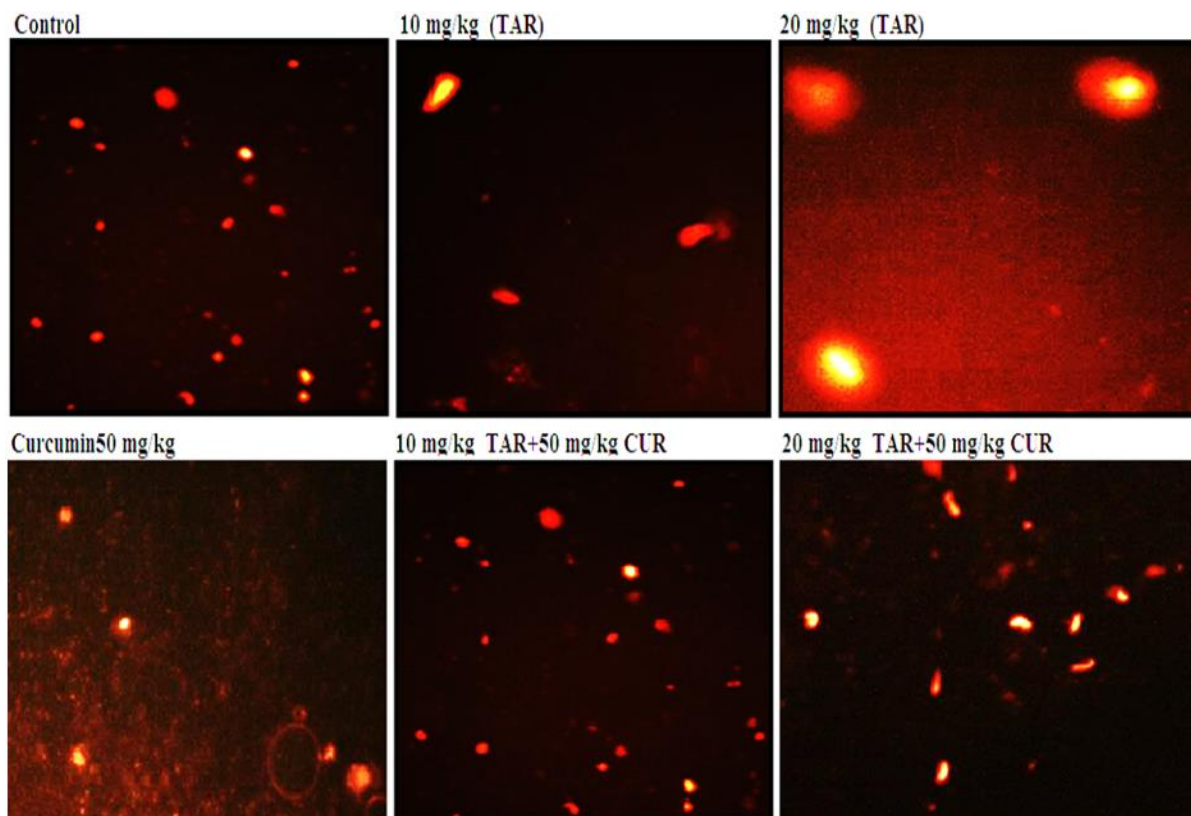


Fig. 3: Comet assay for DNA damage in Testes tissues in various studied groups. Where G1, control group; G2, 10g/kg (TAR) group; G3, 20 mg/kg (TAR) group; G4, 50mg (CUR) G5, 10 TAR+ 50mg/kg CUR) group; G6, 20 TAR+ 50 CUR group.

Histopathological Analysis of Liver:

The control group and 50 mg/kg curcumin administered group showed no histopathological changes. While in the tartrazine-administered group (10 mg/kg TAR), oedemas with inflammatory cell infiltration were detected in the portal veins accompanied by a few fibroblastic cell proliferation and degeneration in the hepatocytes. Moreover, in group 3 (20 mg/kg TAR-treated group): the portal area showed severe congestion in the portal vein associated

with fibrosis between the newly formed bile ductules, whereas the surrounding hepatocytes exhibited degenerative changes. In group 5 (10 mg/kg TAR co-treated with 50 mg/kg curcumin), there was no histopathological alteration with a few inflammatory cell infiltrations in the portal vein. In group 6 (20 mg/kg TAR co-treated with 50 mg/kg curcumin), mild degeneration and congestion were observed in hepatocytes (Fig. 4).

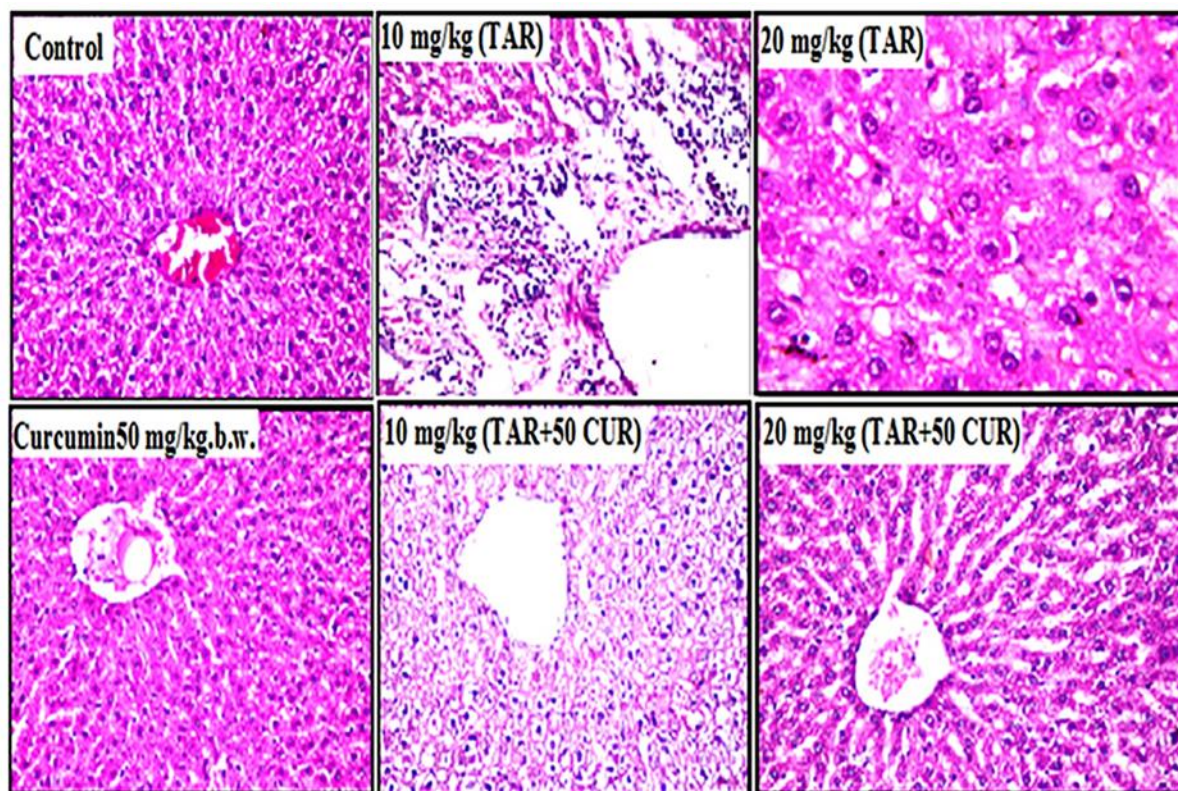


Fig. 4 a: Control group: No histopathological changes were detected, and the central vein and surrounding hepatocytes in the parenchyma retained their normal histological structure. **b** 10 mg/kg tartrazine-administered group: Oedemas with inflammatory cell infiltration were detected in the portal area in association with dilatation in the portal vein, and massive inflammatory cell aggregation was detected in the portal area, accompanied by few fibroblastic cell proliferation and degeneration in the hepatocytes. Severe dilatation of the central vein was observed (10 mg/kg [TAR]). **c** 20 mg/kg tartrazine-treated group: The portal area showed severe congestion in the portal vein associated with fibrosis between the newly formed bile ductules, whereas the surrounding hepatocytes exhibited degenerative changes and severe dilatation and congestion were noticed in the central vein (20 mg/kg (TAR)). **d** Rats were only administered 50 mg/kg curcumin, and no histopathological alterations were observed. **e** 10 mg/kg tartrazine with 50 mg/kg curcumin-treated group: There was no histopathological alteration in the central vein and surrounding hepatocytes in the parenchyma, and the portal area showed dilatation in the portal vein associated with a few inflammatory cell infiltrations. **f** 20 mg/kg tartrazine with 50 mg/kg curcumin-treated group: Mild degeneration was detected in hepatocytes and associated with congestion in the portal vein and edema in the portal area.

Histopathological Analysis of Kidneys:

TAR administration resulted in significant histological impairments in renal tissue in dose dependent manner. In group 5 (50 mg/kg curcumin group and 10 mg/kg TAR administered with 50 mg/kg curcumin), no histopathological changes were reported.

In group 6 (20 mg/kg TAR administered with 50 mg/kg curcumin), there was little vacuolization in the endothelial cells lining the tufts of the glomeruli with degeneration in the lining tubular epithelium at the cortex (Fig. 5).

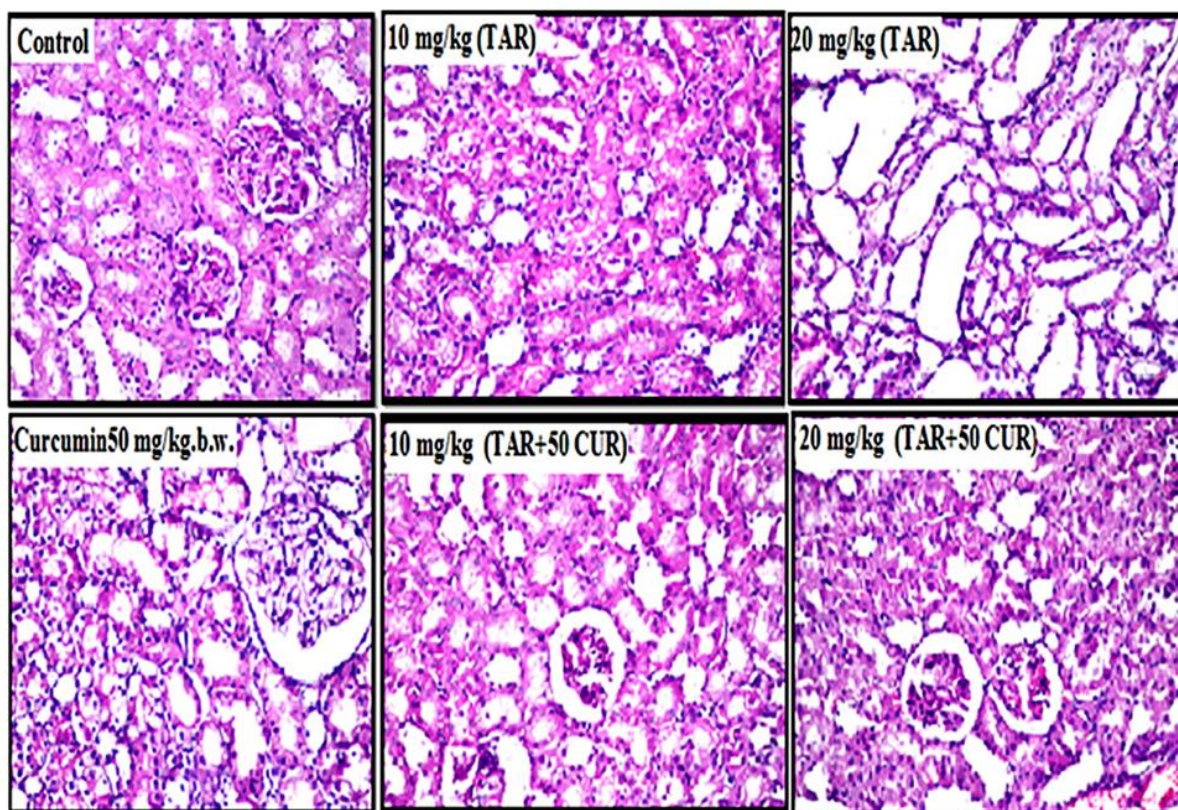


Fig. 5 a: Control group: There were no histopathological alterations or normal histological structures of the glomeruli and tubules in the cortex (control). **b** 10 mg/kg tartrazine-treated group: Congestion was observed in sclerotic blood vessels in the cortex, associated with degeneration of the tubular lining epithelium. **c** 20 mg/kg tartrazine-treated group: The lining tubular epithelium at the cortex showed degeneration and swelling, and cystic dilatation was noticed in the lumen of the tubules in the corticomedullary region **d** Group of rats administered 50 mg/kg curcumin only: no histopathological change was reported. **e** 10 mg/kg tartrazine, with 50 mg/kg curcumin-treated group: no histopathological change was reported. **f** 20 mg/kg tartrazine with 50 mg/kg curcumin-treated group: There was little vacuolization in the endothelial cells lining the tufts of the glomeruli and an association with degeneration in the lining tubular epithelium at the cortex.

Histopathological Analysis of Testes:

Control showing the normal histological structure of the mature active seminiferous tubules. 10 mg/kg TAR group showed atrophy, degeneration, and azospermia in some seminiferous tubules. The group treated with 20 mg/kg TAR showed atrophy and azospermia in the

individual seminiferous tubules. In group3 (50 mg/kg curcumin-administrated rats), stained sections showed normal architecture of testicular tissue. In groups 5 and 6 (10 mg/kg TAR + 50 mg/kg curcumin and 20 mg/kg TAR + 50 mg/kg curcumin), no histopathological alterations were observed (Fig. 6).

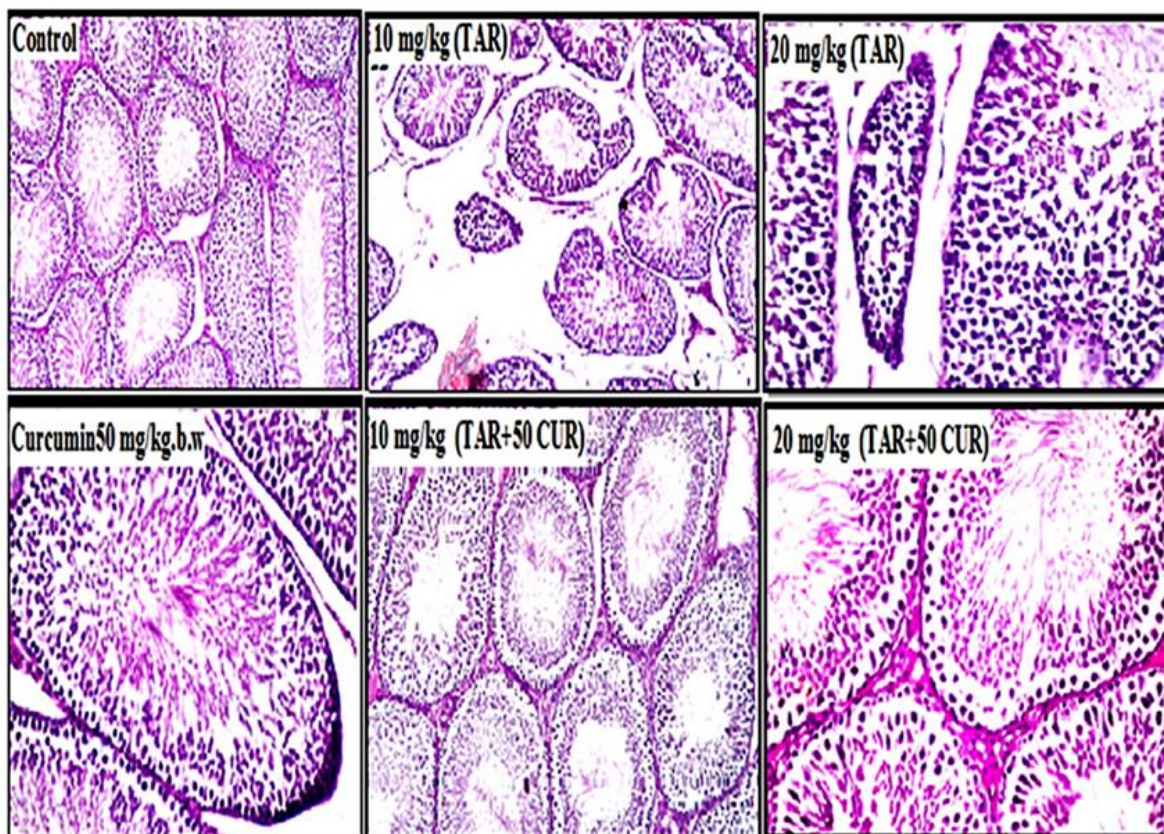


Fig. 6: Pathological changes in testicular tissue. **a** Control showing no histopathological alteration, and the normal histological structure of the mature active seminiferous tubules with a complete spermatogenic series and interstitial Leydig cells were recorded. **b** The group treated with 10 mg/kg tartrazine showed atrophy, degeneration, and azospermia in some seminiferous tubules. **c** Group treated with 20 mg/kg tartrazine showed atrophy and azospermia in the individual seminiferous tubules. **d** Group of rats administered 50 mg/kg curcumin only: there was no histopathological alteration. **e** 10 mg/kg tartrazine, and 50 mg/kg curcumin-treated group; there were no histopathological alterations. **f** 20 mg/kg tartrazine, with 50 mg/kg curcumin-treated group showed no histopathological alterations were observed.

DISCUSSION

The global food industry is increasingly utilizing food additives of both natural and synthetic origins. Therefore, food products may contain toxic additives (Vidotti *et al.*, 2005). One class of food additives is coloring agents, such as food dyes, which are intended to increase the aesthetic appearance of foods and make them more attractive to consumers. Unfortunately, many synthetic colorants have been found to possess carcinogenic, genotoxic, and mutagenic properties (Himri *et al.*, 2012; Khayyat *et al.*, 2017; Dos Santos *et al.*, 2022). Tartrazine (E102), a synthetic food dye, is frequently used as an additive in the food industry (Walton *et al.*, 1999). These nitrous

compounds extracted from coal tar have been previously studied for mutagenicity and carcinogenesis, as they can produce aromatic amines and sulfanilic acid via the intestinal microflora (Chung *et al.*, 1992; Elhkim *et al.*, 2007). These metabolites can induce free radical production and generate oxidative stress (Himri *et al.*, 2011). To investigate tartrazine's toxicity to vital organs, including the liver, kidney, and testes, we have designed a protocol that takes into account concentration factor as well as exposure length by administering low and high doses of tartrazine for 30 and 60 days.

The present study demonstrated a slight but significant increase in body weight and a slight but significant decrease in organ

weight after tartrazine administration, in a dose-dependent manner. However, the clinical significance of these findings remains unclear. Himri *et al.* (2012) found insignificant changes in body weight after tartrazine treatment. In contrast, El-Desoky *et al.* (2017) reported lower body mass gain, especially in female mice, which was attributed to lower caloric intake. These discrepancies could be attributed to the fact that this response depends on various factors, such as appetite, food palatability, caloric content, metabolic rates, and hormonal status of the animal models, as well as the duration of exposure and doses.

In our study, AST and ALT, indicative of liver function, showed abnormal levels, reaching the highest level after 60 days of high-dose tartrazine administration. This effect may be due to the damage to the liver membrane. These results clearly indicate that both concentration and duration are important in determining the toxicity profile of tartrazine. Similarly, Saxena and Sharma (2015) showed that daily intake of artificial food colorant compounds for 30 days resulted in impaired hepatic function. Consistent with the biochemical results, tartrazine administration caused histopathological alterations, including hepatocyte necrosis, infiltration, and vacuolation. Other studies have reported histopathological and biochemical alterations in the liver after tartrazine administration (Al-Shinnawy, 2008; Al-Seenii *et al.*, 2018). Similarly, histopathological changes were reported in the hepatocytes of guinea pigs exposed to tartrazine in drinking water for 3 weeks (Rus *et al.*, 2010).

The current study also showed renal function impairment after tartrazine administration, as evidenced by significantly higher urea and creatinine levels in the tartrazine-received groups relative to the normal and curcumin groups. The renal function tests were further exacerbated after 60 days of tartrazine administration, especially in the high-dose group. Our results agree with those documented by Mehedi *et al.* (2009), Nabila *et al.*, (2013) and Al-Seenii *et*

al. (2018). They indicated that administering tartrazine at low and high doses resulted in a notable rise in urea and creatinine levels. These findings clearly indicated a decline in renal function and implied an inefficient kidney filtration. In the current work, prolonged exposure to tartrazine (60 days) might contribute to a cumulative effect of tartrazine toxicity and a progressive worsening of kidney function. In line with our study, Hassan (2010) found an overt effect on kidney function after 7 weeks of treatment with tartrazine. Amin *et al.* (2010) reported a similar effect on biochemical markers of renal damage. The detrimental effect of tartrazine on the kidney can be attributed to the generation of oxidative stress in various cell structures, particularly the cell membranes. The administration of tartrazine showed histopathological consequences on the renal tissues of rats, as demonstrated by degeneration, swelling, and cystic dilatation in the lumen of the tubules (Fig.5). In agreement with our study, Amin *et al.* (2010) reported degeneration of kidney tissues in rats treated with tartrazine. We hypothesized that the histopathological changes observed in the kidneys following tartrazine administration might be attributed to the oxidative stress caused by tartrazine. Curcumin succeeded in reversing the adverse effects of tartrazine on renal histopathology, suggesting a potential role as an antioxidant in mitigating tartrazine-induced kidney damage. It has been shown that the beneficial effect of curcumin could be mediated by modulating inflammatory markers, oxidative stress, and DNA damage (Benzer *et al.*, 2018). This finding is consistent with the results of the present study.

Regarding the effect of tartrazine on the testes, the current work demonstrated overt toxicity, as evidenced by low sperm count, low free and total testosterone, and aberrant histopathological structures of testicular tissue. Our results align consistently with those documented previously (Mehedi *et al.*, 2009; Visweswaran, 2012; Al-Seenii *et al.*, 2018; Aksu *et al.*, 2019). All of these studies reported a reduction in the testicular sperm

count and morphological abnormalities after tartrazine administration. Additionally, exposure to tartrazine generates high ROS levels, thereby inflicting damage on the testicular tissue and leading to sperm aberrations (Boussada *et al.*, 2017). ROS levels have also been linked to male infertility pathophysiology (Tremellen, 2008), sperm DNA damage, reduced fertilization and embryo development, a lowered implantation rate, and the occurrence of miscarriage (Agarwal *et al.*, 2006). In the current study, curcumin administration ameliorated testicular function and resulted in substantial restoration of spermatogenesis in seminiferous tubules. The present study is in accordance with a recent study showing the palliative effect of curcumin on testicular damage (Aksu *et al.*, 2019).

In all biochemical tests, it was found that the dosage of tartrazine was more crucial in inducing tartrazine toxicity than the duration of exposure, as shown by the results of all parameters. The higher-dose-lower exposure was worse than the lower-dose-higher exposure for inducing tartrazine toxicity. This implies that further reducing tartrazine dosage in foodstuffs might dilute its long-term effects by facilitating effective xenobiotic clearance, and allowing the body to tolerate low tartrazine intake.

Regarding the genotoxicity of tartrazine, the current study showed that tartrazine caused DNA damage in all organs, as evidenced by the comet assay. Our findings agree with those of previous studies suggesting the genotoxic effects of tartrazine and mitotic spindle disorders in animal models (Himri *et al.*, 2012; Hashem *et al.*, 2019; Dos Santos *et al.*, 2022). The genotoxic effect of tartrazine is likely a result of its direct interaction with nuclear DNA (Mpountoukas *et al.*, 2010; Himri *et al.*, 2012). Alternatively, this dye induces oxidative stress through its ability to generate free radicals, which may damage the DNA. Hassan (2010) showed that a daily dosage of tartrazine (7.5 and 15 mg/kg b.wt.) administered to rats for seven weeks caused DNA damage in the kidney and liver.

Recently, embryotoxic and teratogenic potential has been reported in rats (Hashem *et al.*, 2019). In our study, curcumin exhibited efficacy in protecting tissue DNA, as was observed in the curcumin-treated groups. Similarly, recent studies (Ji, 2010; Roy *et al.*, 2011; Ogiwara *et al.*, 2013; Yardım *et al.*, 2020) showed that curcumin protects against DNA damage and increases the DNA repair capacity of lymphocytes exposed to Arsenic toxicity. Ogiwara *et al.* (2013) reported that curcumin represses various pathways involved in DNA damage.

In our study, reduced tissue antioxidant levels of GSH, CAT, and SOD were observed. Additionally, there was a significant increase in ROS and malondialdehyde (MDA), a lipid peroxidation marker, suggesting oxidative stress damage in tartrazine-treated rats. Oxidative stress can occur as a result of accelerated ROS production and/or a deficiency of antioxidant mechanisms (Poprac *et al.*, 2017). The present findings agree with a study reporting an oxidative damage of tartrazine in Chinese hamsters and attributed lipid peroxidation to ROS generation after tartrazine administration (Demirkol *et al.*, 2012). Tartrazine, an azo dye food colorant, is metabolized by the intestinal microflora into aromatic amines. These amines can produce ROS by interacting with foods containing nitrates or nitrites (Moutinho *et al.*, 2007). Regular consumption of tartrazine has been found to increase oxidative stress levels in different tissues of Wistar rats (Himri *et al.*, 2012). ROS overproduction causes oxidative stress, which leads to organ and tissue damage (Abdel-Daim *et al.*, 2020; Gad El-Hak and Mobarak, 2020). Tartrazine suppressed mitochondrial respiration in the kidneys and liver of rats (Reyes *et al.*, 1996). Impaired membrane integrity may cause this disruption in mitochondrial function. According to Bakar and Aktac (2014), the degeneration of the mitochondrial membrane can negatively impact the oxidative metabolism of cells.

Curcumin is commonly used as an anti-inflammatory, antioxidant, and

anticancer agent. This ability is ascribed to its free radical-scavenging capacity. Given the increasing exposure of humans to various xenobiotics in manufactured foods, there is a great demand for natural products with antioxidant properties to be incorporated into foodstuffs. In the current study, curcumin was found to exert a protective effect against tartrazine toxicity in the liver, kidneys, and testes. This prophylactic effect is primarily attributed to the free radical-scavenging ability of curcumin. Moreover, curcumin effectively inhibits lipid peroxidation and alleviates oxidative stress by increasing intracellular GSH levels and modulating antioxidant genes (Kadasa *et al.*, 2015; Yardim *et al.*, 2020). Additionally, nucleic acid binding has been demonstrated for curcumin, and this interaction may provide insights into the anticancer properties of curcumin (Kunwar *et al.*, 2011). Curcumin successfully normalized the histopathological patterns of the liver, kidneys, and testes against tartrazine-induced toxicity in a dose-dependent manner. Nevertheless, further investigation is required to clarify the molecular mechanisms involved in the prophylactic and therapeutic role of curcumin in different organs following tartrazine administration. Therefore, determining the optimal dose of curcumin prophylaxis warrants further research.

Conclusions

Curcumin can restore antioxidant balance within cells and efficiently reduce the oxidative stress triggered by tartrazine administration. Its antioxidant properties can enhance organ protection against tartrazine-induced toxicity. As low-dose tartrazine can be tolerated, restriction of its use has become a justified claim. An enhanced supplement of curcumin is recommended to counteract the intake of tartrazine from various food sources. Given that children often consume excessive coloring agents in food, there may be increasing health concerns that necessitate more initiation from parents and health providers to restrict tartrazine intake by choosing safer food options. Raising awareness of the adverse effects of synthetic

colors remains an urgent need. Further investigation to standardize the intake of natural colors as food additives is in high demand.

List of abbreviations

Tartazine	TAR
Curcumin	CUR
Glutathione	GSH
Catalase	CAT
Superoxide dismutase	SOD
Reactive oxygen species	ROS
Malondialdehyde	MDA

Declarations:

Ethical Approval: All animal procedures were in accordance with the recommendations of the Canadian Committee for Care and were approved by the October 6 University and the Institutional Animal Ethics Committee of the Egyptian Drug Authority. The ethical approval number for experimental study provided by October 6 University is: 20230710.

Competing interests: The authors declare that they have no competing interests.

Authors Contributions: SK contributed to the study conception and has written the first draft of the manuscript. All authors participated in the design of the study, material preparation, animal experiments, data collection, and analysis. IL and SK have done blood biochemical analysis and genotoxicity tests. MD performed the histopathological examination. All authors have commented on the previous versions of the manuscript. All authors have read and approved the final manuscript.

Availability of Data And Materials:

Funding: No funding was granted for this study.

Acknowledgements: Not applicable

REFERENCES

- Ab. AL-Shinnawy M (2008) Assessment of the changes in some diagnostic parameters in male albino rats (*Rattus norvegicus*) intoxicated with thiodicarb insecticide. *Egyptian Academic Journal of Biological Sciences A. Entomology*, 1:157–166. <https://doi.org/10.21608/eajbsa.200>

- 8.15747
- Abdel-Daim MM, Abushouk AI, Bahbah EI, et al (2020) Fucoidan protects against subacute diazinon-induced oxidative damage in cardiac, hepatic, and renal tissues. *Environmental Science and Pollution Research*, 27:11554–11564. <https://doi.org/10.1007/s11356-020-07711-w>
- Abdel-Moemin, A.R., 2016. Analysis of the content, colourants, fats, nitrate and nitrite in advertised foods and biological fluids of Egyptian children. *British Food Journal*, 118(11), pp.2692-2709.
- Aebi HE (1984) Catalase in vitro. *Methods of enzymology*, 105:121–126. <https://doi.org/https://doi.org/10.1002/jbt.20091>
- Ahmed, M.A., Al-Khalifa, A.S., Al-Nouri, D.M. and El-Din, M.F.S., 2021. Dietary intake of artificial food color additives containing food products by school-going children. *Saudi Journal of Biological Sciences*, 28(1), pp.27-34.
- Agarwal A, Sharma RK, Nallella KP, et al (2006) Reactive oxygen species as an independent marker of male factor infertility. *Fertility and sterility*, 86:878–885. <https://doi.org/10.1016/j.fertnstert.2006.02.111>
- Aksu EH, Kandemir FM, Yıldırım S, et al (2019) Palliative effect of curcumin on doxorubicin-induced testicular damage in male rats. *Journal of Biochemical and molecular toxicology*, 33:. <https://doi.org/10.1002/jbt.22384>
- Al-Seeni MN, El Rabey HA, Al-Hamed AM, Zamazami MA (2018) Nigella sativa oil protects against tartrazine toxicity in male rats. *Toxicological reports*, 5:146–155. <https://doi.org/10.1016/j.toxrep.2017.12.022>
- Amin KA, Abdel Hameid H, Abd Elsttar AH (2010) Effect of food azo dyes tartrazine and carmoisine on biochemical parameters related to renal, hepatic function and oxidative stress biomarkers in young male rats. *Food and Chemical Toxicology* 48:2994–2999. <https://doi.org/10.1016/j.fct.2010.07.039>
- Amin, K.A. and Al-Shehri, F.S., 2018. Toxicological and safety assessment of tartrazine as a synthetic food additive on health biomarkers: A review. *African Journal of Biotechnology*, 17(6), pp.139-149.
- Bakar E, Aktaş T (2014) Effects of Sodium Benzoate and Citric Acid on Serum, Liver and Kidney Tissue Total Sialic Acid Levels: An Ultrastructural Study. *Journal of Applied Biological Sciences*, 8:9–15
- Bartels H, Böhmer M, Heierli C (1972) Serum kreatininbestimmung ohne enteissen. *Clinica chimica acta* 37:193–197. [https://doi.org/10.1016/0009-8981\(72\)90432-9](https://doi.org/10.1016/0009-8981(72)90432-9)
- Benzer F, Kandemir FM, Kucukler S, et al (2018) Chemoprotective effects of curcumin on doxorubicin-induced nephrotoxicity in wistar rats: by modulating inflammatory cytokines, apoptosis, oxidative stress and oxidative DNA damage. *Archives of physiology and biochemistry*, 124:448–457. <https://doi.org/10.1080/13813455.2017.1422766>
- Boussada M, Lamine JA, Bini I, et al (2017) Assessment of a sub-chronic consumption of tartrazine (E102) on sperm and oxidative stress features in Wistar rat. *International food research journal*, 24:1473–1481
- Caglayan C, Temel Y, Kandemir FM, et al (2018) Naringin protects against cyclophosphamide-induced hepatotoxicity and nephrotoxicity through modulation of oxidative stress, inflammation, apoptosis, autophagy, and DNA damage. *Environmental Science and Pollution Research*, 25:20968–20984. <https://doi.org/10.1007/s11356-018-2242-5>
- Chung KT, Stevens SE, Cerniglia CE (1992) The reduction of azo dyes by the

- intestinal microflora. *Critical reviews in microbiology*, 18:175–190. <https://doi.org/10.3109/10408419209114557>
- Clemens, R., Pressman, P. and Hayes, A.W., 2023. Food additives toxicology. In *History of Food and Nutrition Toxicology*, (pp. 87-102). Academic Press.
- Demirkol O, Zhang X, Ercal N (2012) Oxidative effects of Tartrazine (CAS No. 1934-21-0) and New Coccin (CAS No. 2611-82-7) azo dyes on CHO cells. *Journal für Verbraucherschutz und Lebensmittelsicherheit*, 7:229–236. <https://doi.org/10.1007/s00003-012-0782-z>
- Dos Santos JR, de Sousa Soares L, Soares BM, et al (2022) Cytotoxic and mutagenic effects of the food additive tartrazine on eukaryotic cells. *BMC Pharmacology and Toxicology*, 23:95. <https://doi.org/10.1186/s40360-022-00638-7>
- Drury R (1983) *Theory and Practice of Histological Techniques*, 4th edn. Churchill Livingstone, New York
- El-Desoky GE, Abdel-Ghaffar A, Al-Othman ZA, et al (2017) Curcumin protects against tartrazine-mediated oxidative stress and hepatotoxicity in male rats. *European Review for Medical & Pharmacological Sciences*, 21:635–645
- El-wakf AM, El-kholy WM (2011) Use of Tumeric and Curcumin to Alleviate Adverse Reproductive Outcomes of Water Nitrate Pollution in Male Rats. *Enzyme*, 9:229–239
- Elhkim MO, Héraud F, Bemrah N, et al (2007) New considerations regarding the risk assessment on Tartrazine. An update toxicological assessment, intolerance reactions and maximum theoretical daily intake in France. *Regulatory Toxicology and Pharmacology* 47:308–316. <https://doi.org/10.1016/j.yrtph.2006.11.004>
- Fawcett JK, Scott JE (1960) A rapid and precise method for the determination of urea. *Journal of clinical pathology*, 13:156–159. <https://doi.org/10.1136/jcp.13.2.156>
- Gad El-Hak HN, Mobarak YM (2020) Copper oxychloride-induced testicular damage of adult albino rats and the possible role of curcumin in healing the damage. *Environmental Science and Pollution Research*, 27:11649–11662. <https://doi.org/10.1007/s11356-020-07715-6>
- Gyori, B.M., Venkatachalam, G., Thiagarajan, P.S., Hsu, D. and Clement, M.V., 2014. OpenComet: an automated tool for comet assay image analysis. *Redox biology*, 2, pp.457-465.
- Gornall AG, Bardawill CJ, David MM (1949) Determination of serum proteins by means of the biuret reaction. *Journal of Biological Chemistry*, 177:751–766. [https://doi.org/10.1016/s0021-9258\(18\)57021-6](https://doi.org/10.1016/s0021-9258(18)57021-6)
- Govindarajan VS (1980) Turmeric—chemistry, technology, and quality. *Critical Reviews in Food Science & Nutrition* 12:199–301. <https://doi.org/10.1080/10408398009527278>
- Hashem MM, Abd-Elhakim YM, Abo-EL-Sooud K, Eleiwa MME (2019) Embryotoxic and teratogenic effects of tartrazine in rats. *Toxicological research*, 35:75–81. <https://doi.org/10.5487/TR.2019.35.1.075>
- Hassan GM (2010) Effects of some synthetic coloring additives on DNA damage and chromosomal aberrations of rats. *Arab Journal of Biotechnology*, 13:13–24
- Himri I, Bellahcen S, Souna F, et al (2011) A 90-day oral toxicity study of Tartrazine, a synthetic food dye, in Wistar rats. *International Journal of Pharmacy and Pharmaceutical Science*, 3:159–169
- Himri I, Souna F, Aziz M, et al (2012) DNA damage induced by tartrazine in rat whole blood using comet assay

- (Single cell gel electrophoresis). *Advances in Environmental Biology*, 6:2875–2881
- Indira Priyadarsini K (2013) Chemical and Structural Features Influencing the Biological Activity of Curcumin. *Current pharmaceutical design*, 19:2093–2100. <https://doi.org/10.2174/138161213805289228>
- Ji Z (2010) Targeting DNA damage and repair by curcumin. *Breast cancer: basic and clinical research*, 4:1
- Joint FAO/WHO Expert Committee on Food Additives. Meeting, 1999. Compendium of Food Additive Specifications: Addendum 7. Food & Agriculture Org..
- Kadasa NM, Abdallah H, Afifi M, Gowayed S (2015) Hepatoprotective effects of curcumin against Diethyl nitrosamine induced hepatotoxicity in albino rats. *Asian Pacific Journal of Cancer Prevention*, 16:103–108. <https://doi.org/10.7314/APJCP.2015.16.1.103>
- Kamal AA, Fawzia SE-S (2018) Toxicological and safety assessment of tartrazine as a synthetic food additive on health biomarkers: A review. *African Journal of Biotechnology*, 17:139–149. <https://doi.org/10.5897/ajb2017.16300>
- Khayyat L, Essawy A, Sorour J, Soffar A (2017) Tartrazine induces structural and functional aberrations and genotoxic effects in vivo. *Peer J* 2017:1–14
- Kunwar A, Simon E, Singh U, et al (2011) Interaction of a Curcumin Analogue Dimethoxycurcumin with DNA. *Chemical biology & drug design*, 77:281–287. <https://doi.org/10.1111/j.1747-0285.2011.01083.x>
- Mahfouz H (2013) Protective action of vitamin C against mutagenic effects of synthetic food color tartrazine. *African Journal of Pharmacy and Pharmacology*, 7:2474–2483. <https://doi.org/10.5897/ajpp2013.3561>
- Marklund S, Marklund G (1974) Involvement of the Superoxide Anion Radical in the Autoxidation of Pyrogallol and a Convenient Assay for Superoxide Dismutase. *European journal of biochemistry*, 47:469–474. <https://doi.org/10.1111/j.1432-1033.1974.tb03714.x>
- Mehedi N, Ainad-Tabet S, Mokrane N, et al (2009) Reproductive toxicology of tartrazine (FD and C Yellow No. 5) in Swiss albino mice. *American Journal of Pharmacology and Toxicology*, 4:130–135. <https://doi.org/10.3844/ajtpsp.2009.130.135>
- Moutinho ILD, Bertges LC, Assis RVC (2007) Prolonged use of the food dye tartrazine (FD&C yellow no5) and its effects on the gastric mucosa of Wistar rats. *Brazilian journal of biology*, 67:141–145. <https://doi.org/10.1590/S1519-69842007000100019>
- Mpountoukas P, Pantazaki A, Kostareli E, et al (2010) Cytogenetic evaluation and DNA interaction studies of the food colorants amaranth, erythrosine and tartrazine. *Food and chemical toxicology*, 48:2934–2944. <https://doi.org/10.1016/j.fct.2010.07.030>
- Murray RK, Bender DA, Botham KM, et al (2009) Chapter 53: Metabolism of Xenobiotics. In: Rodwell VW, Bender DA, Botham KM, et al. (eds) *Harper's Illustrated Biochemistry*, 28th ed. McGraw-Hill Education, New York, NY
- Nabila M, Nawel M, Omar A, et al (2013) A thirteen week ad libitum administration toxicity study of Tartrazine in Swiss mice. *African journal of biotechnology*, 12:4519–4529. <https://doi.org/10.5897/ajb2013.12125>
- Ogiwara H, Ui A, Shiotani B, et al (2013) Curcumin suppresses multiple DNA damage response pathways and has potency as a sensitizer to PARP inhibitor. *Carcinogenesis*, 34:2486–2497. <https://doi.org/10.1093/carcin/bgt240>

- Poprac P, Jomova K, Simunkova M, et al (2017) Targeting Free Radicals in Oxidative Stress-Related Human Diseases. *Trends in pharmacological sciences*, 38:592–607. <https://doi.org/10.1016/j.tips.2017.04.005>
- Rahmani AH, Alsahli MA, Aly SM, et al (2018) Role of Curcumin in Disease Prevention and Treatment. *Advanced biomedical research*, 7:38. https://doi.org/10.4103/abr.abr_147_16
- Rahnama, H., Mazloomi, S.M., Berizi, E., Abbasi, A. and Gholami, Z., 2022. Identification of Tartrazine adulteration and evaluating exposure to synthetic dyes of sunset yellow and Quinoline yellow through consumption of food products among children. *Food Science & Nutrition*, 10(11), pp.3781-3788.
- Reitman S, Frankel S (1957) A colorimetric method for the determination of serum glutamic oxalacetic and glutamic pyruvic transaminases. *American journal of clinical pathology*, 28:56–63. <https://doi.org/10.1093/ajcp/28.1.56>
- Reyes FGR, Valim MFCFA, Vercesi AE (1996) Effect of organic synthetic food colours on mitochondrial respiration. *Food Additives & Contaminants*, 13:5–11. <https://doi.org/10.1080/02652039609374376>
- Roy M, Sinha D, Mukherjee S, Biswas J (2011) Curcumin prevents DNA damage and enhances the repair potential in a chronically arsenic-exposed human population in West Bengal, India. *European Journal of Cancer Prevention*, 20:123–131. <https://doi.org/10.1097/CEJ.0b013e328341017a>
- Rus V, Gherman C, Miclăuş V, et al (2010) Comparative toxicity of food dyes on liver and kidney in guinea pigs: A histopathological study. *Annals of the Romanian Society for Cell Biology*, 15:161–165
- Sasaki YF, Kawaguchi S, Kamaya A, et al (2002) The comet assay with 8 mouse organs: Results with 39 currently used food additives. *Mutation Research/Genetic Toxicology and Environmental Mutagenesis*, 519:103–119. [https://doi.org/10.1016/S1383-5718\(02\)00128-6](https://doi.org/10.1016/S1383-5718(02)00128-6)
- Saxena B, Sharma S (2015) Food color induced hepatotoxicity in Swiss albino rats, *Rattus norvegicus*. *Toxicology international*, 22:152–157. <https://doi.org/10.4103/0971-6580.172286>
- Siddiqui FA, Prakasam G, Chattopadhyay S, et al (2018) Curcumin decreases Warburg effect in cancer cells by down-regulating pyruvate kinase M2 via mTOR-HIF1 α inhibition. *Scientific reports*, 8:8323. <https://doi.org/10.1038/s41598-018-25524-3>
- Sönmez M, Türk G, Yüce A (2005) The effect of ascorbic acid supplementation on sperm quality, lipid peroxidation and testosterone levels of male Wistar rats. *Theriogenology*, 63:2063–2072. <https://doi.org/10.1016/Journaloftheriogenology.2004.10.003>
- Tong R, Wu X, Liu Y, et al (2020) Curcumin-Induced DNA Demethylation in Human Gastric Cancer Cells Is Mediated by the DNA-Damage Response Pathway. *Oxidants and Medical Cell Longevity* 2020:2543504. <https://doi.org/10.1155/2020/2543504>
- Tremellen K (2008) Oxidative stress and male infertility - A clinical perspective. *Human reproduction update*, 14:243–258. <https://doi.org/10.1093/humupd/dmn004>
- Uchiyama M, Mihara M (1978) Determination of malonaldehyde precursor in tissues by thiobarbituric acid test. *Analytical Biochemistry*, 86:271–278. [https://doi.org/10.1016/0003-2697\(78\)90342-1](https://doi.org/10.1016/0003-2697(78)90342-1)

- Vidotti EC, Cancino JC, Oliveira CC, Rollemberg MDCE (2005) Simultaneous determination of food dyes by first derivative spectrophotometry with sorption onto polyurethane foam. *Analytical sciences*, 21:149–153. <https://doi.org/10.2116/analsci.21.149>
- Visweswaran B (2012) Oxidative Stress by Tartrazine in the Testis of Wistar Rats. *Journal of Pharmacy and Biological Sciences* 2:44–47. <https://doi.org/10.9790/3008-0234447>
- Vrablic AS, Albright CD, Craciunescu CN, et al (2001) Altered mitochondrial function and overgeneration of reactive oxygen species precede the induction of apoptosis by 1-O-octadecyl-2-methyl-rac-glycero-3-phosphocholine in p53-defective hepatocytes. *The Faseb journal*, 15:1739–1744. <https://doi.org/10.1096/fj.00-0300com>
- Walton K, Walker R, Van De Sandt JJM, et al (1999) The application of in vitro data in the derivation of the acceptable daily intake of food additives. *Food and Chemical Toxicology*, 37:1175–1197. [https://doi.org/10.1016/S0278-6915\(99\)00107-6](https://doi.org/10.1016/S0278-6915(99)00107-6)
- Yardim A, Kandemir FM, Çomaklı S, et al (2020) Protective Effects of Curcumin Against Paclitaxel-Induced Spinal Cord and Sciatic Nerve Injuries in Rats. *Neurochemical research*, 46:379–395. <https://doi.org/10.1007/s11064-020-03174-0>