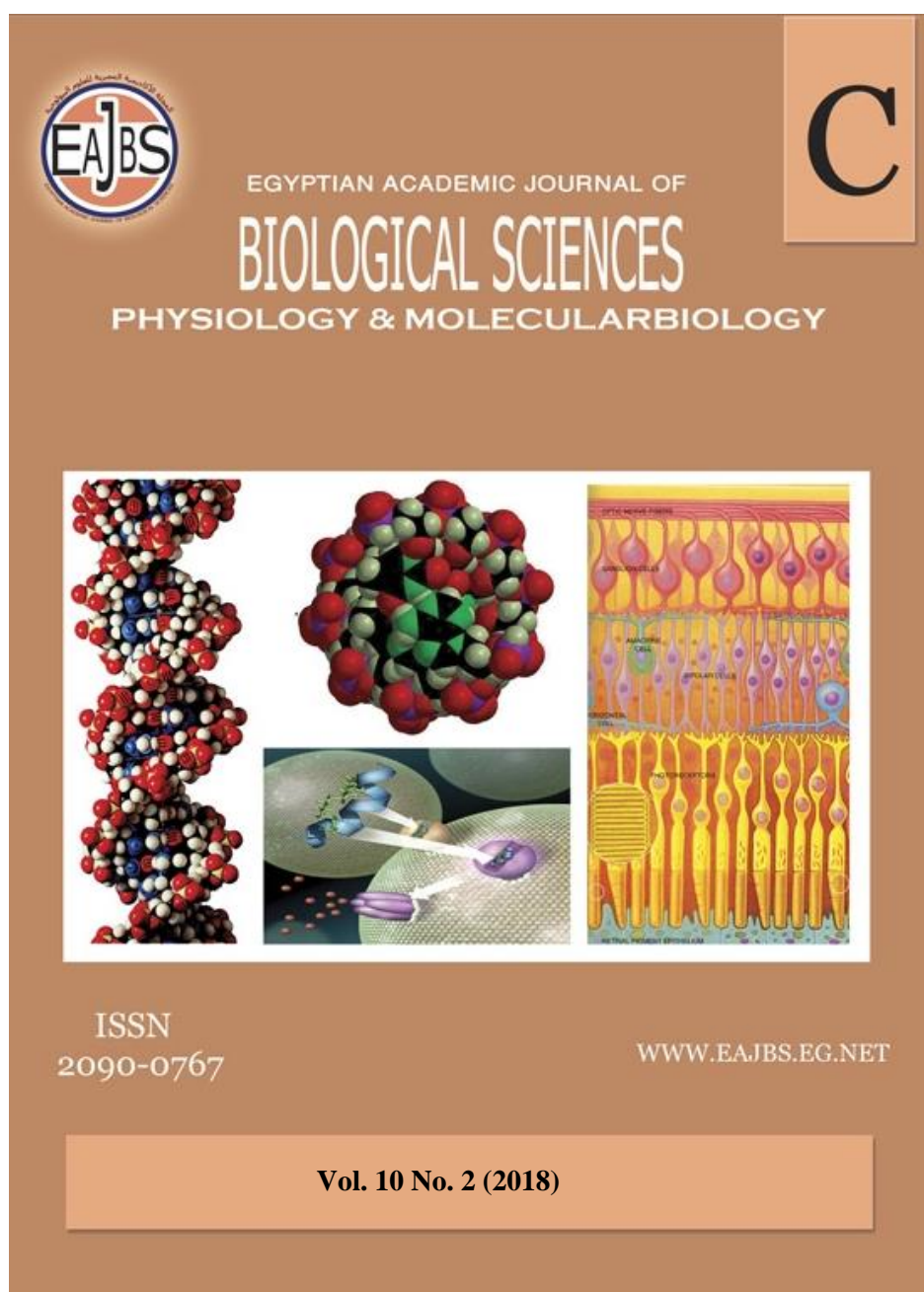


Provided for non-commercial research and education use.

Not for reproduction, distribution or commercial use.



Egyptian Academic Journal of Biological Sciences is the official English language journal of the Egyptian Society for Biological Sciences, Department of Entomology, Faculty of Sciences Ain Shams University.

C. Physiology & Molecular Biology journal is one of the series issued twice by the Egyptian Academic Journal of Biological Sciences, and is devoted to publication of original papers that elucidate important biological, chemical, or physical mechanisms of broad physiological significance.

<http://ejbsd.journals.ekb.eg/>



Tramadol Biological Effects: I: Effective Therapeutic Efficacy of *Lagenaria siceraria* Preparation (Gamal & Aref¹) and Melatonin on Cell Biological, Histochemical and histopathological Changes in Ileum of Tramadol-Induced Male Mice

Abdel-Baset M. Aref¹, Maha A. Momenah², Mariam M. Jad¹ and Margit Semmler³

1- Zoology Department, Faculty of Science, South Valley University, Egypt. IACUC of SVU in Egypt.

2-Nourah bint Abdulrahman University, KSA.

3- Diabetes Research Institute, Düsseldorf University, Düsseldorf, Germany. IACUC of SVU

#E.Mail : Aref322189@yahoo.com / abdelbaset.aref@sci.svu.edu.eg.

ARTICLE INFO

Article History

Received:5/8/2018

Accepted:15/9/2018

Keywords:

IACUC of SVU

in Egypt-

Biological effect

of Tramadol -

Melatonin -

Lagenaria

siceraria – Male

mice – Ileum.

ABSTRACT

Tramadol is used worldwide and is listed in many medical guidelines to treat both acute and chronic pain. There is growing evidence of abuse of tramadol in some African and West Asian countries. Tramadol has some side effects. The present study was designed a follow-up and treatment of the cell biological, histochemical and Pathological response which might be induced in the ileum of tramadol application. A total number of 70 adult males Swiss albino mice were obtained and survived during experiments from/in (Autoradiographic lab. of Cell Biology and Immunology studies, Faculty of Science, South Valley University), under supervision Dr. Abdel-baset Aref Mohamed. At the time of the experiments, the mice were aged 90 ± 5 days and weighed 30 ± 2 g. All male mice were kept under the same conditions of light-dark cycle (12h-12h), temperature ($23 \pm 2^\circ\text{C}$), and humidity (37-40%). They were supplied standard food and water *ad libitum*. The daily injections of tramadol for 20 reaches to 40 days highly changed the volume of nuclei and protein, RNA and DNA materials contained in the cells lining ileum, therefore, extensively and severely destructions showed in the normal histological architecture of ileum of male mice.

Finally, we could say, Although, tramadol has many cytological, histochemical and histopathological, side effects on ileum of male mice but the treatments with *Lagenaria siceraria* and melatonin have a more effective therapeutic effect on tramadol side effects.

INTRODUCTION

The opioid is considered first-line treatment for hospitalized patients with moderate to severe pain (Holden *et al.*, 2005). They are currently the most effective pain-relieving pharmaceuticals. Opioids are the most potent and effective analgesics available and became accepted as appropriate treatment for acute, cancer and non-cancer chronic pain (Collet, 2001). However, they are also rewarding and their repeated use can lead to dependence and addiction.

In fact, addiction to opioid analgesics is a growing socioeconomic and health problem with potentially serious consequences documented by a rise in deaths due to overdose (Hall *et al.*, 2008). In the United States, the medical use of opioids has increased dramatically in the past two decades (Okie, 2010).

A parallel rise in opioid-related adverse effects such as emergency room visits and overdose mortality has also occurred (Bohnert *et al.*, 2011). In palliative care, the commonly prescribed opioids include tramadol, morphine, fentanyl, methadone, buprenorphine, diamorphine, oxycodone and codeine, and these drugs exhibit multi-system effects due to their interactions with receptors that are targeted by the endogenous opioid system. Tramadol is a synthetic, centrally acting analgesic, available in Europe since 1977 and in the United States since 1995 for treatment of pain syndromes previously amenable only to the opiate analogues (Moore *et al.*, 1999).

In human and veterinary medicine, tramadol has been in clinical use for the relief of mild to moderate pain (Pypendop and Ilkiw, 2008). Also, tramadol is used perioperatively in veterinary anesthesia as it significantly reduces the requirements of volatile anesthetics and opioid agents (Seddighi *et al.*, 2009).

Tramadol has a dual mode of action. Its analgesic efficacy is attributed to its partial affinity for the μ -opiate receptor and its inhibition of norepinephrine and serotonin reuptake (Shadnia *et al.*, 2008). Tramadol is considered a safe drug devoid of many serious adverse effects of traditional opioids. However, recently, abuse and dependence of tramadol as well as toxicity and tramadol related deaths have been increasingly reported (Tjäderborn *et al.*, 2007).

Lagenaria siceraria was used as an antidote to certain poisons. It

possesses antioxidant, anthelmintic, antibacterial, antifungal, immunomodulatory, anti-allergic, analgesic, anti-inflammatory, free radical scavenging, cytotoxic, antihyperlipidemic antidiabetic, hepatoprotective, anxiolytic and memory-enhancing properties (Aslam and Najam, 2013). Also, it was proved that melatonin is an extremely potent free radical scavenger and antioxidant (Poeggeler *et al.*, 1993). The enhancement of intracellular ROS proliferation in different tissues was observed after melatonin administration (Cao *et al.*, 2013).

Melatonin, a hormone produced by the pineal gland, is a potent scavenger of reactive oxidative radicals (Reiter *et al.*, 2000). Thus, Melatonin can prevent free radical-induced cellular oxidative damage and can contribute to the physiological functions of the antioxidant defensive system (Kumar *et al.*, 1999). Also, it can stimulate several antioxidant systems, thereby facilitating more antioxidant activities and stabilizing cell membranes. In addition, it modulates the gene expression of several protective enzymes and reduces apoptosis and lipid peroxidation (Reiter, 1998).

Melatonin and its metabolites have an anti-inflammatory property and have been proven to be highly effective in a variety of disorders linked to inflammation and oxidative stress. (Carrillo *et al.*, 2005) A melatonin supplement can decrease oxidative stress in renal tissues and attenuate kidney scarring. In a model of cyclosporine-induced nephropathy, pretreatment with melatonin decreased tubular and glomerular damage (Kumar *et al.*, 1999).

MATERIALS AND METHODS

Animals: a total number of 70 adult males Swiss albino mice were obtained from Autoradiographic lab. of Cell Biology and Immunology studies, Faculty of Science, South Valley

University, under supervision Dr. Abdel-baset Aref Mohamed. At the time of the experiments, the mice were aged 90 ± 5 days and weighed 30 ± 2 g of each mouse. All male mice were kept under the same conditions of an artificial light-dark cycle (12h-12h), temperature ($23 \pm 2^\circ\text{C}$), and humidity (37-40%). They were supplied standard food and water *ad libitum*.

Chemicals:

1- **Tramadol HCl ampoules** were purchased from October Pharma S.A.E., 6 October City, Egypt) was diluted with distilled water to a concentration of 150ug/1ml.

2- **Melatonin** [Sigma-Aldrich, Co. 3050 spruce street, St. Louis, MO 63103 USA 314-771-5765] was dissolved in a few drops of absolute ethanol and diluted with distilled water to a concentration of 500 $\mu\text{g/ml}$.

3- **Lagenaria siceraria**: special preparation of *Lagenaria siceraria*, (Gamal & Aref₁), were prepared by Gamal Yagteen and Abdel-baset Aref via squeezer in 6 October City, Egypt.

Experimental Design:

2 sets of experiments were performed differing in exposure to the various treatments.

Experiment I:-

Treated animals were divided into 3 groups, including 10 males each.

Group T₁: animals were daily subcutaneously injected with tramadol Hcl (125ug / 100g b.w.) for 20 days.

Group T₂: animals were daily subcutaneously injected with tramadol Hcl (125ug / 100g b.w.) for 40 days.

Group C: animals were daily subcutaneously injected with distilled water (0.25ml/ 30g b.w.) and served as control.

All animals were sacrificed the day following the last injection.

Experiment II:-

All male mice were injected subcutaneously with a daily injection of tramadol (125ug / 100g b.w) for 40 days and subdivided into 4 groups, concluding 10 males each, designated as groups T, S, L and M as follows:

Group T: Animals were treated with tramadol only.

Group S: tramadol-treated animals were injected with a daily injection of distilled water (0.25ml / 30g b.w.) for 40 days.

Group L: tramadol-treated animals were treated with a daily oral dose of a special preparation of *Lagenaria siceraria* (Gamal Yagteen₁ & Abdel-baset Aref₁) (0.5 mg/ b.w.) for 40 days.

Group M: tramadol-treated animals were daily injected with a subcutaneous injection of Melatonin (100 μg / 100g b.w.) for 40days at 16h, 2h before the end of the light cycle for 40 days.

The mice of group T in experiment II were similar to mice of group T₂ in experiment I, which were daily injected with tramadol for 40 days only before sacrificed.

All animals were sacrificed the day following the last injection or oral dose.

Experiments of this research were conducted in lab. achieve stability of environmental conditions, separation between treated animals and control ones and IACUC targets.

IACUC Approval Project Number:

IACUC-SVU-EYGPT		0	0	1
SVU/FS		4/2016-PN		(1)

Tissues Preparation:

Tissues specimens of ileum excised, fixed in neutral formalin 10%, dehydrated in graded series of ethanol, cleared, embedded in paraffin wax and sectioned at 5 microns thickness.

Karyometric studies were applied to H & E-stained ileum. The volume of cell nuclei was performed using camera program (LAS ZA). A total number of (200) nuclei were measured/animal. The measurements were carried out in two ways according to shape nucleus.

The first concerned rounded nuclei of cells where the formula of the

sphere was applied: $V = \frac{4}{3} \pi r^3$

The second concerned oval nuclei of cells. The volume of the nucleus was obtained by means of revolution spheroid: $V = \frac{\pi}{6} AP^2$

Where: A - longer diameter & P - short diameter

All methods were applied according to Pearse (1980), Carleton *et al.*, 1980 and Lewinski *et al.*, 1984.

RESULTS

Cell Biological Changes

(Karyometric Studies): -

Experiment I:

In the ileum of control mice, the value of mean volume nuclei of epithelial cells lining villi was 98 μ (Table 1). While in the ileum of the mice which daily received tramadol for 20 days (T1) or 40 days (T2), the value of mean volume nuclei of epithelial cells lining villi was 48 μ and 19 μ respectively.

From the quantitative point of view, the daily injection of tramadol for 20 or 40 days decreased the mean volume value of nuclei of epithelial cells lining villi in the ileum of mice by 51 % and 80% respectively versus those of control mice. While the daily injection of tramadol for 40 days (T2) decreased 60 % the mean volume value of nuclei of epithelial cells lining

villi versus those of mice of (T1) (Table 1).

From the cytological point of view, although the tramadol showed an inhibitory effect on the nuclei volume of epithelial cells lining villi in ileum of mice, but with time, this inhibitory effect decreased.

Experiment II:

The ileum of mice after 40 days from stop tramadol injection (TS) the nuclei of epithelial cells lining villi showed a mean volume value of 58 μ , while in ileum of the mice which received *Lagenaria siceraria* (TL) or melatonin (TM) for 40 days, the mean volume value of nuclei in both groups was 57 μ and 63 μ respectively, (Table 1).

From the quantitative point of view, the treatments with stopping tramadol or *Lagenaria siceraria* or melatonin increased by 202%, 200%, and 231 % respectively versus those of mice that receiving tramadol only for 40 days (Table 1).

From the cytological point of view, all previous treatments revealed an inhibitory effect on the changes induced by tramadol on volume nuclei of epithelial cells lining villi in ileum in mice but did not reach to control mice.

Table 1: Mean volume of nuclei in epithelial cells lining villi in ileum of control (C) and tramadol-treated male mice for 20, 40 days (T₁, T₂) and tramadol-treated male mice for 40 days (T), tramadol treated mice for 40 days and then treated with distilled water (S) or *Lagenaria siceraria* oil (L) or melatonin (M) for 40 days. The percentage of mean volume stimulation (S %) or inhibition (I %) is given.

Ileum	Experiment 1			Experiment 2			
	C	T ₁	T ₂	T	S	L	M
Groups							
Measurements							
Mean volume nuclei (\pm S.E) of the epithelial cells lining villi	98.9 \pm 11.8 μ	48.6 \pm 1.0 μ	19.2 \pm 2.8 μ	19.2 \pm 2.8 μ	58.0 \pm 2.7 μ	57.7 \pm 1.3 μ	63.7 \pm 8.1 μ
(S%) or (I%) of mean volume nuclei of the epithelial cells lining villi	←	I=51%		←	S=202%		
	←		I=80%	←		S=200%	
		←	I=60%	←			S=231%

S.E.: standard error of the mean

**Histochemical Changes: -
DNA Content Changes (Feulgen
reaction): -**

Experiment I:

The ileum of control mice (C) stained with DNA stain showed high DNA contents with sharply stained coloration in nuclei of epithelial cells lining ileum of mice (Figs. 1 & 2) and (Table 2). The ileum of the mice received tramadol (T1) showed few DNA contents with faintly stained coloration (Figs. 3 & 4) and (Table 2). The ileum of the mice received tramadol (T2) showed few DNA contents with faintly stained coloration (Figs. 5 & 6).

The daily injection of tramadol for 20 or 40 days decreased markedly DNA materials content in epithelial cells lining ileum of mice versus control.

Experiment II:

The mice after stop tramadol injection (TS) showed moderate DNA contents with moderately stained coloration (Figs 7 & 8) and (Table 2). Ileum of the mice which received tramadol and *Lagenaria siceraria* (TL) showed moderate DNA contents with moderately stained coloration (Figs. 9 & 10) and (Table 2). Ileum of the mice which received tramadol and melatonin (TM) showed high DNA contents with sharply stained coloration (Figs. 11 & 12) and (Table 2).

Although the treatment with stop tramadol or *Lagenaria siceraria* increased slightly the DNA content in nuclei of epithelial cells lining ileum of mice compared with those of mice that received tramadol only for 40 days but melatonin treatment increased markedly the DNA content which reached to those of control mice.

From the histochemical point of view, the tramadol administration showed a remarkable inhibitory effect on the chemical material contents: protein, RNA and DNA content and stimulatory effect on collagen content

epithelium cells lining ileum in mice, but the treatment with melatonin or *Lagenaria siceraria* reduced the inhibitory effect on tramadol side effects shown by histochemical methods.

RNA Content (Toluidine Blue):-

Experiment I:

The ileum of the control mice (C) stained with RNA stain toluidine blue showed high RNA contents with deeply stained coloration in cytoplasm and nucleolus of epithelial cells lining ileum of mice (Figs. 13 & 14) and (Table 2). Ileum of the mice receiving tramadol (T1) showed low RNA contents with faintly stained coloration (Figs 15 & 16) and (Table 2). Ileum of the mice which received tramadol (T2) showed few RNA contents with faintly stained coloration (Figs. 17 & 18).

The daily injection of the only tramadol for 20 and 40 days markedly decreased RNA content in cytoplasm and nucleolus of epithelial cells lining ileum of mice versus control.

Experiment II:

Ileum of the mice after stop tramadol injection (TS) showed moderate RNA contents with moderately stained coloration (Figs. 19 & 20) and (Table 2). Ileum of the mice which received tramadol and *Lagenaria siceraria* (TL) showed moderate RNA contents with moderately stained coloration (Figs. 21 & 22) and (Table 2). Ileum of the mice which received tramadol and then melatonin (TM) showed much higher RNA contents with deeply stained coloration (Figs. 23 & 24) and (Table 2).

Although the treatments with stopping tramadol or *Lagenaria siceraria* increased slightly the RNA materials contents in cytoplasm and nucleolus of epithelial cells lining ileum of mice compared with those of mice which received tramadol only for 40 days, but melatonin treatment increased markedly the RNA contents and reached to those of control mice.

Protein Content (Bromophenol Bleu Technique):-

Experiment I:

The ileum of the control mice(C) stained with bromophenol blue showed high protein content inside epithelial cells lining ileum with deeply blue stainability (Figs.25 & 26) and (Table 2). Ileum of the mice received tramadol (T1) showed weak protein content with weak blue stainability (Figs.27 & 28) and (Table 2). Ileum of the mice receiving tramadol (T2) showed weak protein content with weak blue stainability (Figs.29 &30).

The daily injection of tramadol for 20 or 40 days remarkably decreased protein content inside the epithelial cells lining ileum of mice versus control mice.

Experiment II:

Ileum of the mice after ending tramadol Injection (TS) showed moderately protein content inside epithelial cells with moderate blue stainability (Figs.31 & 32) and (Table 2). Ileum of the mice receiving tramadol and *Lagenaria siceraria* (TL) showed moderately protein content with moderate blue stainability (Figs.33 & 34) and (Table 2). Ileum of the mice received tramadol and melatonin (TM) showed high protein content with sharply blue stainability (Figs.35 & 36) and (Table 2).

Although the treatments with stop tramadol or *Lagenaria siceraria* showed slightly increased the protein content in epithelial cells lining ileum of mice compare with those of mice that received tramadol only for 40 days but melatonin treatment markedly increased the protein content and reached to those of control mice.

Collagen Content (Mallory Trichrome Technique): -

Experiment I:

Ileum of the control mice(C) displayed normal distribution of collagen fibers (Figs.37 & 38) and (Table 2). Ileum of the mice which received daily tramadol for 20 days

(T1) showed high collagen content and high precipitation of deeply stained blue coloration of collagen fibers (Figs. 39 & 40) and (Table 2). Also, ileum of the mice which received daily tramadol for 40 days (T2) showed high collagen with high ileum blue coloration of collagen fibers (Figs. 41 & 42).

The mice which were daily injected with tramadol for both 20 and 40 days remarkable elevated the collagen materials contents in the epithelial cells lining ileum of mice versus control mice.

Experiment II: -

Collagen fibers precipitation was detected highly in the ileum of mice after 40 days from stop tramadol injection (TS) (Figs. 43 & 44) and (Table 2). Moreover, slight collagen fibers precipitation was observed in ileum of the mice receiving daily tramadol for 40 days and then daily *Lagenaria siceraria* for 40 days (TL) or daily melatonin for 40 days (TM) (Figs. 45, 46, & 47 &48) and (Table 2).

Except for treatment with stop tramadol injection, the treatments with both, *Lagenaria siceraria* and melatonin, decreased markedly collagen materials contents in ileum compare with those of mice which reserved melatonin for 40 days and also reached to normal level of collagen.

Histopathological Changes of the Ileum (H & E Technique): -

Experiment I:

The control mice (C) displayed normal ileum layers involving mucosa, submucosa, muscularis and serosa (Fig. 49) with ileum villi (Fig. 50) and (Table 3). The ileum of the mice which received daily tramadol for 20 days (T1) showed necrosis and desquamation of the ileum epithelial lining villi (Figs51 & 52) (Table 3). Also, the ileum lumen appeared and filled with tissue debris and edematous fluids (Fig. 53) and severely infiltrated with inflammatory cells (Fig.54).

However, the ileum of the mice which received daily tramadol for 40 days (T₂) recorded extensive necrosis and desquamation of the intestinal tips (Figs.55 & 56) and (Table 3). There was ileum vacuolation and degeneration were recorded (Fig.57).

Daily injection of tramadol for 20 and 40 days partially destroyed the normal histological architecture of ileum of mice

Experiment II:

Ileum of the mice after 40 days from stopping tramadol injection (T_s) showed congestion of blood vessels (Fig.58) and (Table 3), besides the thickening of tunica muscularis with fibrous tissues (Fig.59). Also, desquamation and necrosis of the ileum villi were observed (Fig.60). The mice treated with *Lagenaria siceraria* (T_L) exhibited normal arrangement of

the ileum layers and villi (Figs.61) and (Table 3). Moreover, mice treated with melatonin (T_M) showed normal ileum layers (Fig.62) with some inflammatory cell's infiltration (Fig.63&64) and (Table 3).

The daily treatments for 40 days with *Lagenaria siceraria* (T_L) or melatonin (T_M) repair the side effects of a daily injection of tramadol for 40 days on ileum of mice which nearly restored its normal histological architecture.

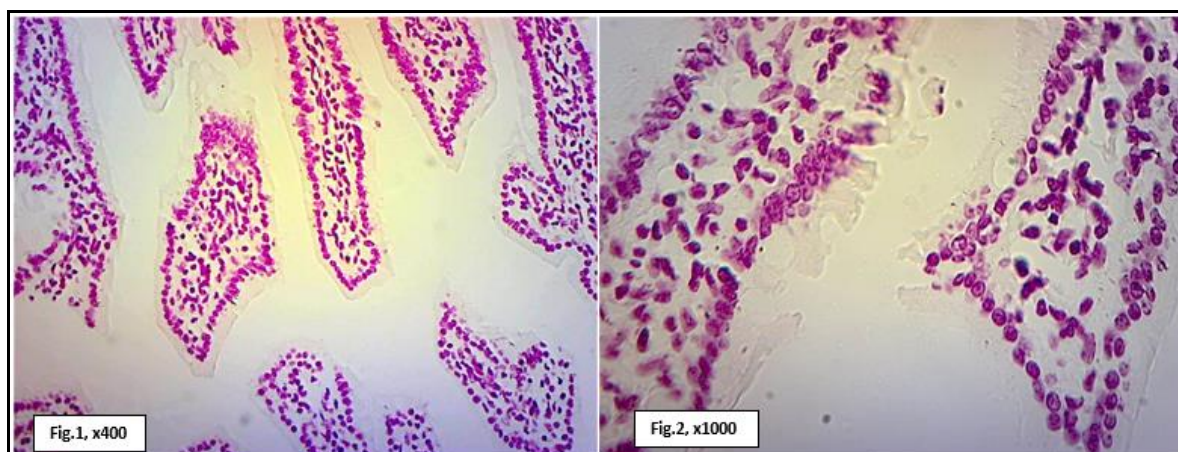
From the histopathological point of view, the tramadol administration induced histopathological side effects on the architecture of ileum in mice, but the *Lagenaria siceraria* or melatonin treatment showed an inhibitory effect on these tramadol side effects.

Table (2): The histochemical score of ileum of mice of groups control (C), injection of tramadol for 20 days (T₁) and 40 days (T₂), tramadol and stopping tramadol injection (T_S), tramadol injection and treated with *Lagenaria siceraria* (T_L) and tramadol injection and treated with melatonin (T_M) stained with bromophenol blue for total protein, Mallory trichrome technique for collagen, toluidine blue for RNA, Feulgen reaction for DNA and PAS for polysaccharides were classified according to severity into severe (+++), moderate (++) , mild (+) and absent (-).

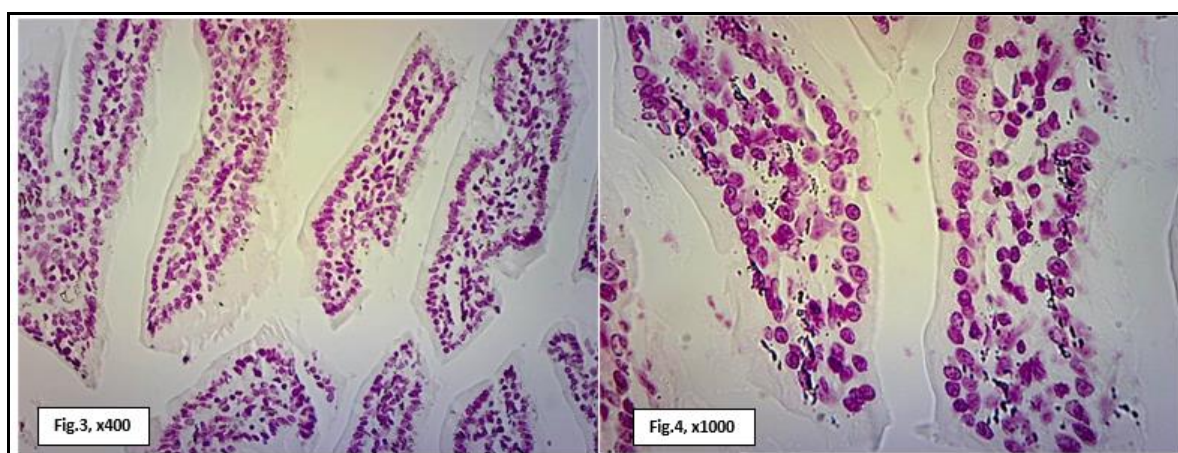
Lesions	Groups					
	C	T ₁	T ₂	T _S	T _L	T _M
Feulgen reaction for DNA content in ileum						
DNA contents	+++	+	+	++	++	+++
Red stained coloration	+++	+	+	++	++	+++
Toluidine blue for RNA content in ileum						
RNA contents	+++	+	+	++	++	+++
Blue stained coloration	+++	+	+	++	++	+++
Bromophenol blue technique for protein contents in ileum						
Protein distribution inside cells	+++	+	+	++	++	+++
blue stained coloration of protein content	+++	+	+	++	++	+++
Mallory trichrome technique for collagen contents in ileum						
Interstitial fibrosis	+	+++	+++	+++	+	+
Perivascular fibrosis	+	+++	+++	+++	+	+
Blue stained coloration of dense collagen fibers	+	+++	+++	+++	+	+

Table (3): Histopathological score of Ileum of mice of groups control (C), injection of tramadol for 20 days (T₁) and 40 days (T₂), tramadol and stopping tramadol injection (T_S), tramadol injection and treated with *Lagenaria siceraria* (T_L) and tramadol injection and treated with melatonin (T_M) stained with H & E were classified according to severity into severe (+++), moderate (++) , few (+) and absent (-).

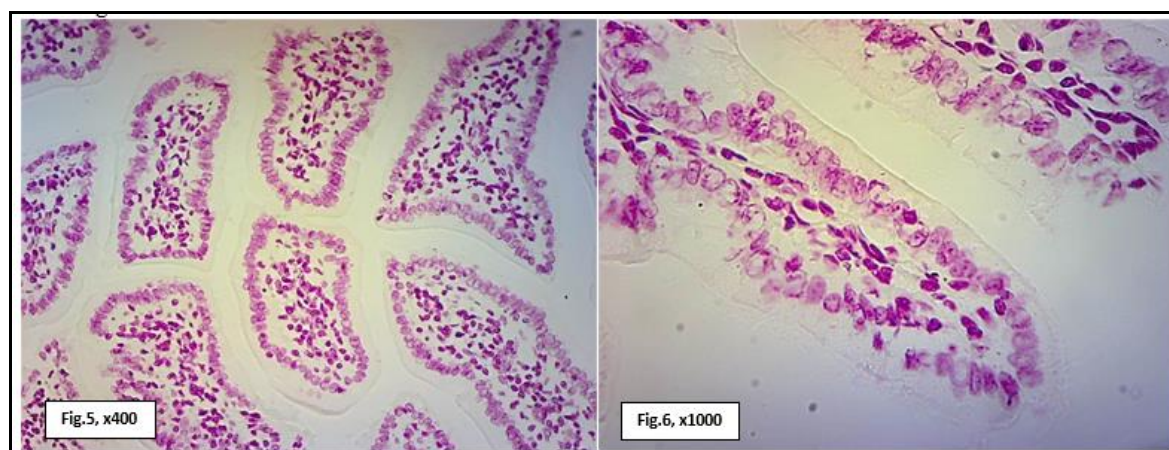
Lesions	Groups					
	C	T ₁	T ₂	T _S	T _L	T _M
Ileum						
Necrosis and desquamation of the intestinal villi	-	+++	+++	++	+	+
Intestinal vacuolation and degeneration	-	+++	+++	++	+	+
Mononuclear cells infiltration	-	+++	+++	++	+	++
Thickening of tunica muscularis with fibrous tissues	-	+++	+++	++	+	+
Congestion of blood vessels	-	+++	+++	+++	+	+



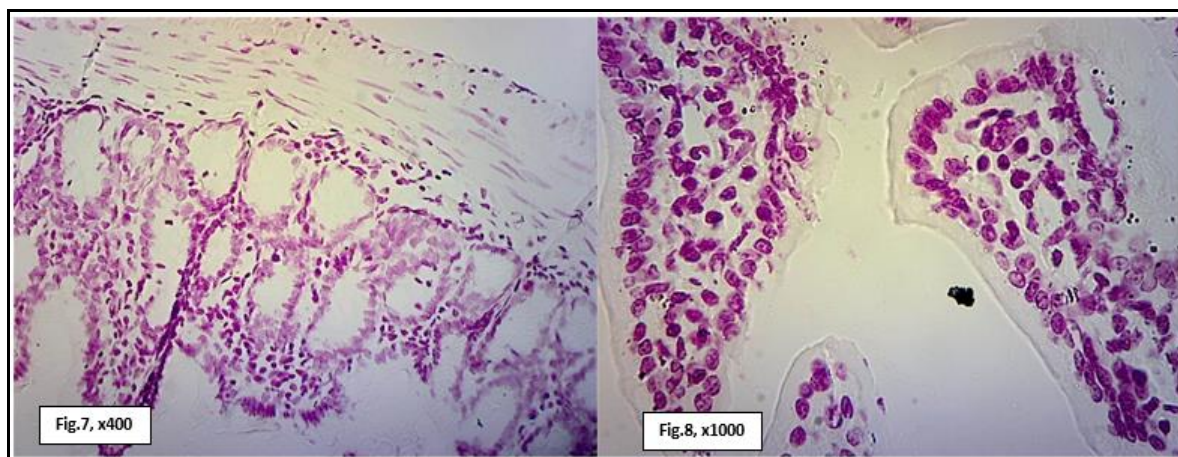
Figs. (1&2): Photomicrographs of the ileum of the control mice(C) stained with Feulgen reaction showing high DNA contents with deeply stained coloration.



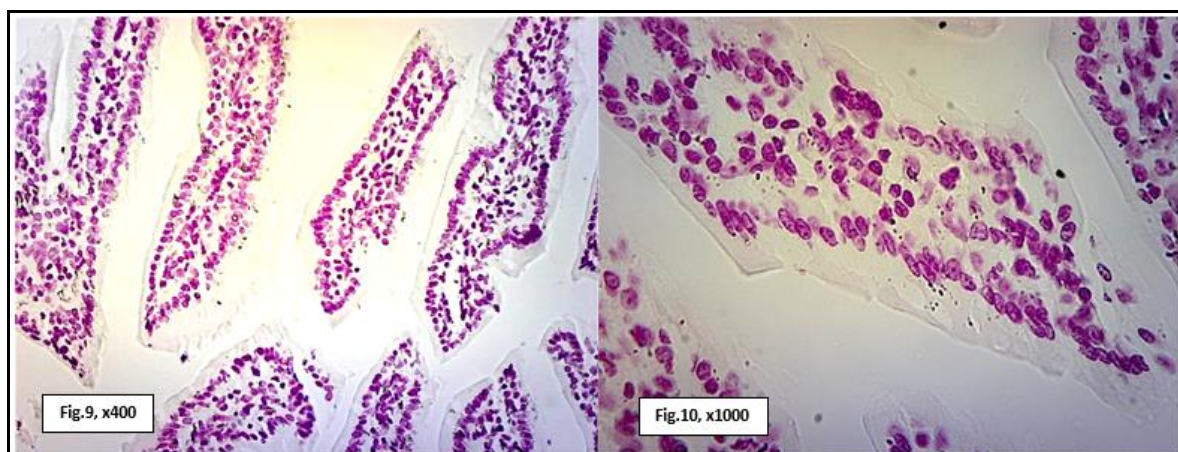
Figs. (3 & 4): Photomicrographs of the ileum of the mice received tramadol (T₁) stained with Feulgen reaction showing few DNA contents with faint stained coloration.



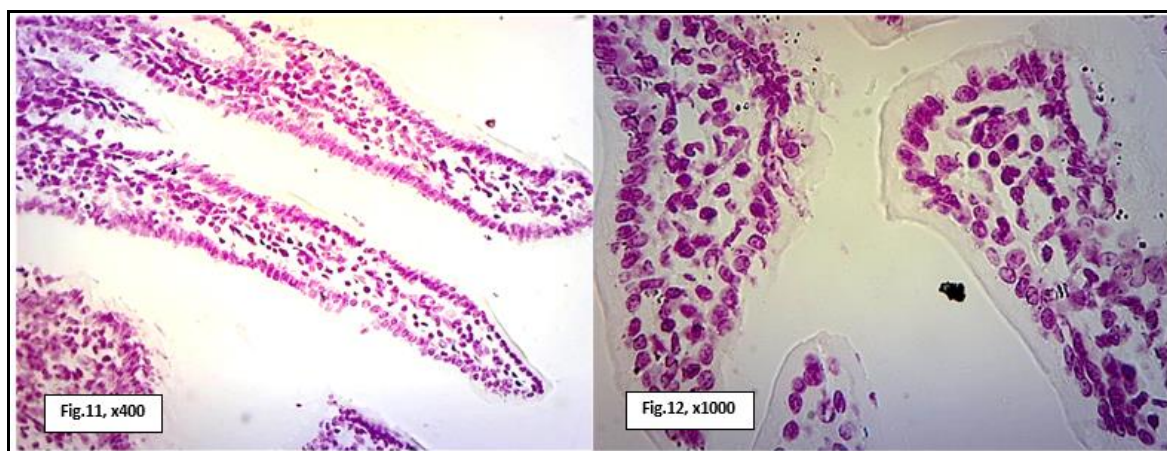
Figs. (5 & 6): Photomicrographs of the ileum of the mice received tramadol (T₂) stained with Feulgen reaction showing few DNA contents with faint stained coloration.



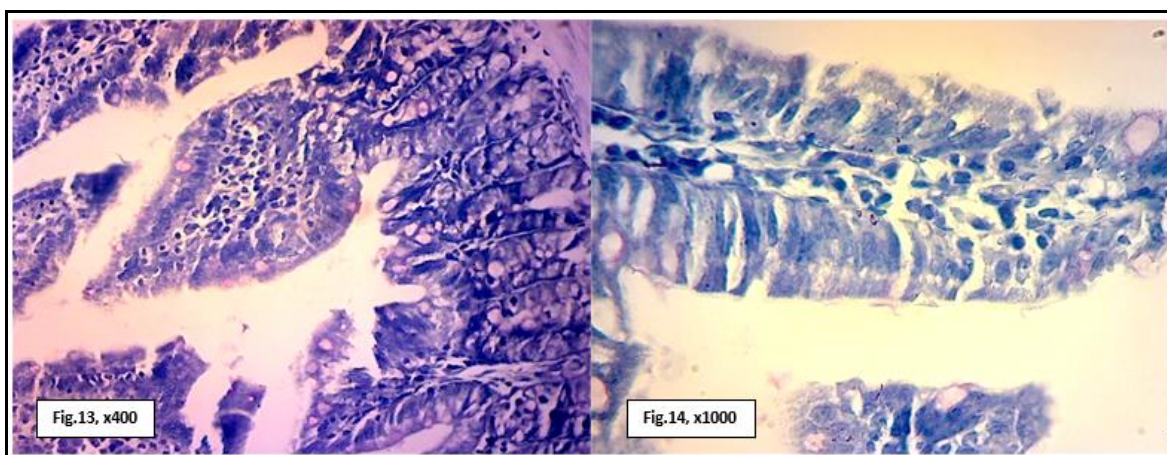
Figs. (7 & 8): Photomicrographs of the ileum of the mice after stopping tramadol injection (T_S) stained with Feulgen reaction showing moderate DNA contents with moderate stained coloration.



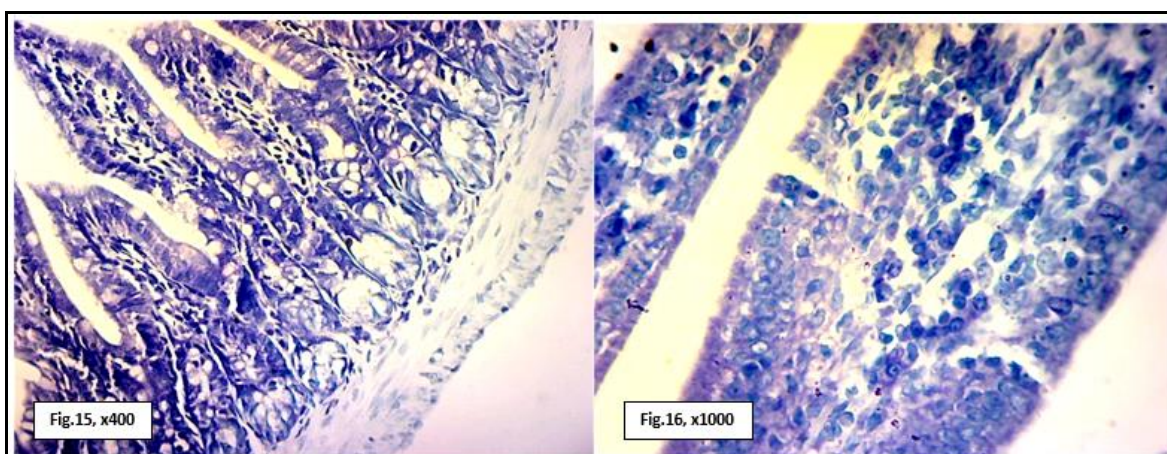
Figs. (9 & 10): Photomicrographs of the ileum of the mice received tramadol and *Legenaria siceraria* (T_L) stained with Feulgen reaction showing moderate DNA contents with moderate stained coloration.



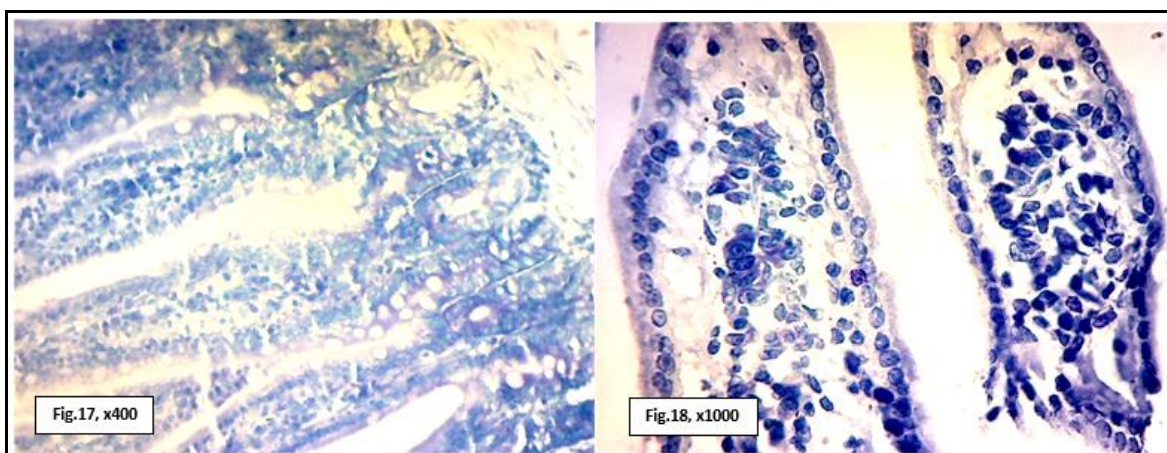
Figs. (11 & 12): Photomicrographs of the ileum of the mice received tramadol and melatonin (T_M) stained with Feulgen reaction showing moderate DNA contents with moderate stained coloration.



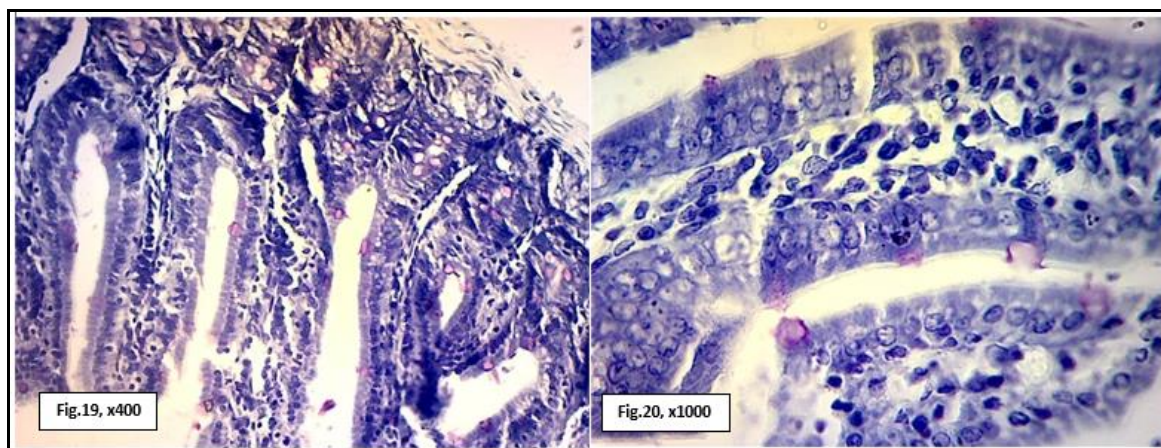
Figs. (13 & 14): Photomicrographs of the ileum of the control mice(C) stained with RNA stain toluidine blue showing high RNA contents with deeply stained coloration.



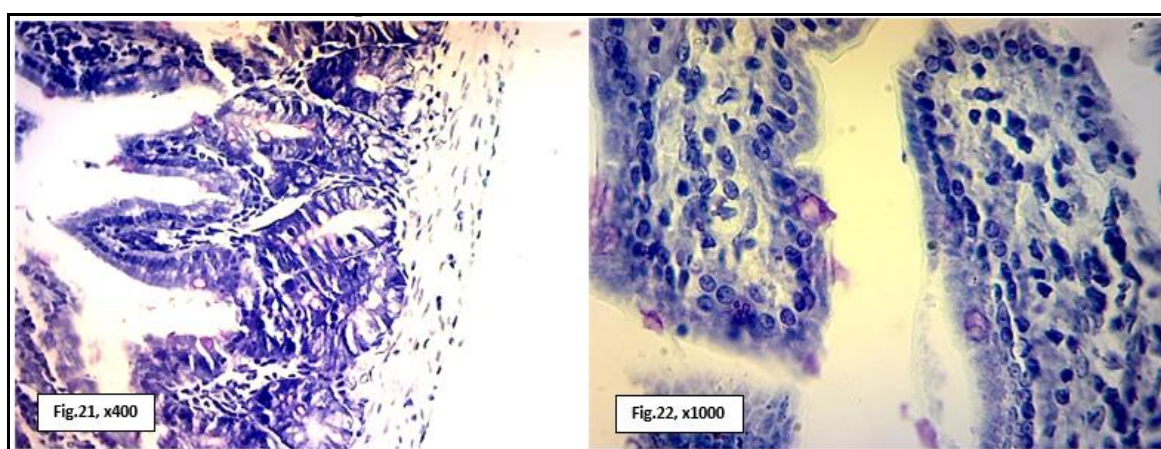
Figs. (15 & 16): Photomicrographs of the ileum of the mice received tramadol (T₁) stained with RNA stain toluidine blue showing low RNA contents with faint stained coloration.



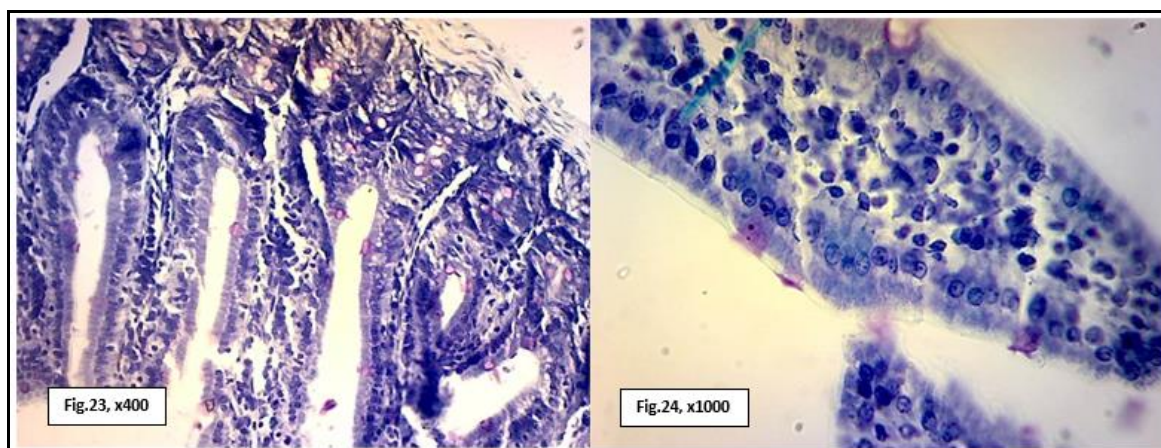
Figs. (17 & 18): Photomicrographs of the ileum of the mice received tramadol (T₂) stained with RNA stain toluidine blue showing few RNA contents with faint stained coloration.



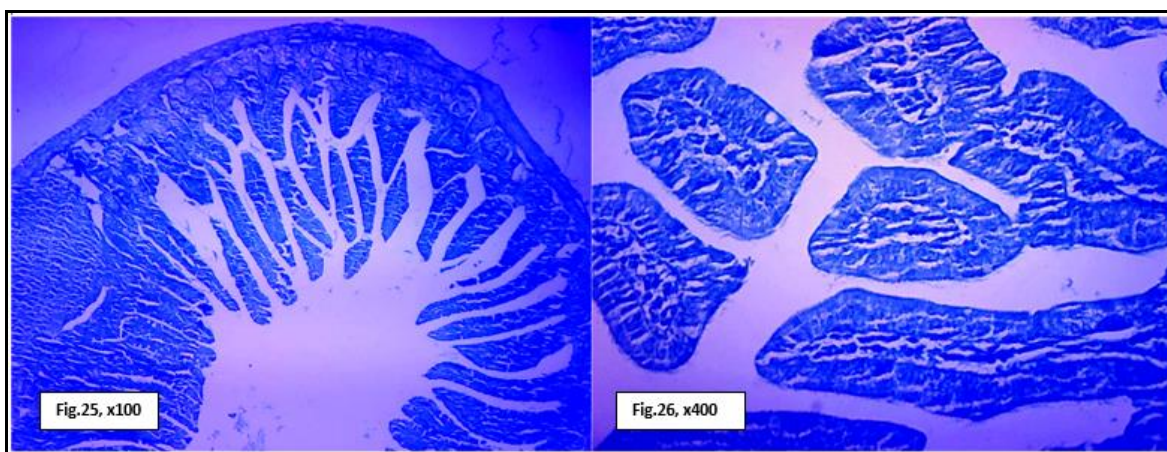
Figs.(19 & 20): Photomicrographs of the ileum of the mice after stopping tramadol injection (T_s) stained with RNA stain toluidine blue showing moderate RNA contents with moderate stained coloration.



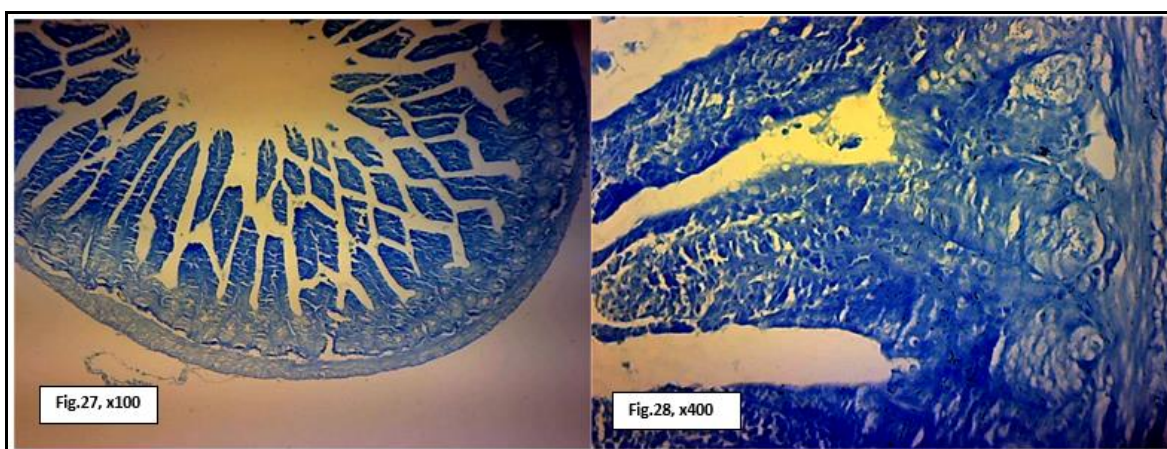
Figs. (21 & 22): Photomicrographs of the ileum of the mice received tramadol and *Lagenaria sicerarai* (T_L) stained with RNA stain toluidine blue showing high RNA contents with deeply stained coloration.



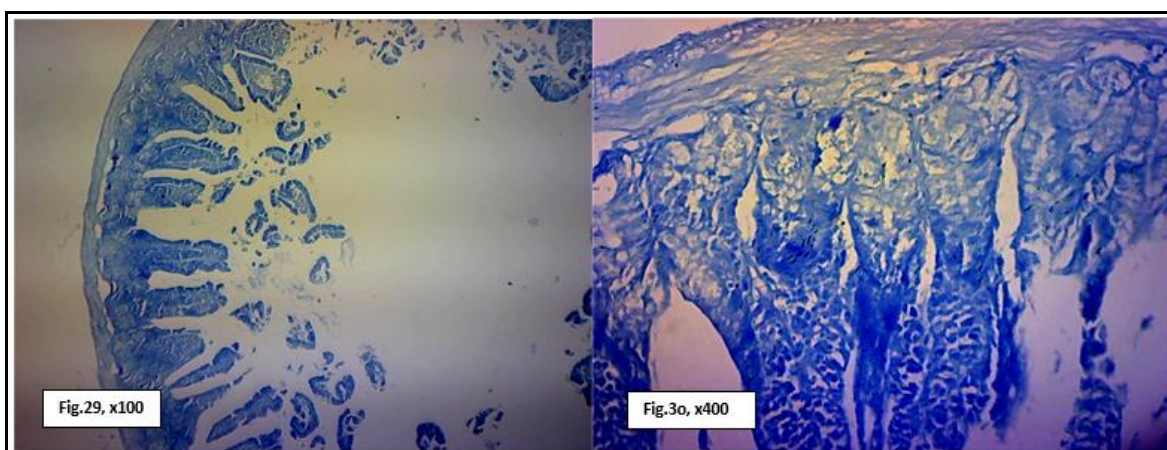
Figs. (23 & 24): Photomicrographs of the ileum of the mice received tramadol and melatonin (T_M) stained with RNA stain toluidine blue showing much RNA contents with deeply stained coloration



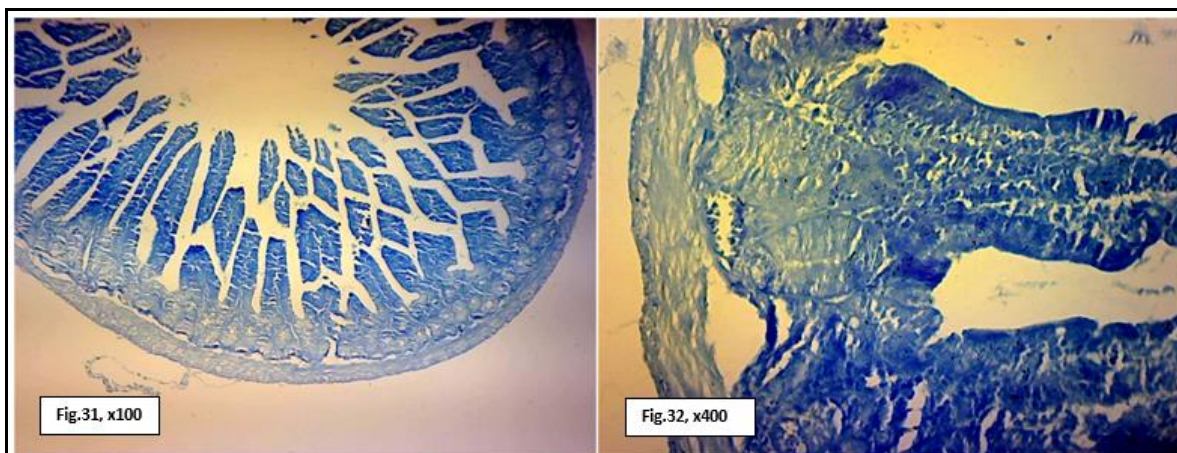
Figs. (25 & 26): Photomicrographs of the ileum of the control mice(C) stained with bromophenol bleu showing high protein content inside cells.



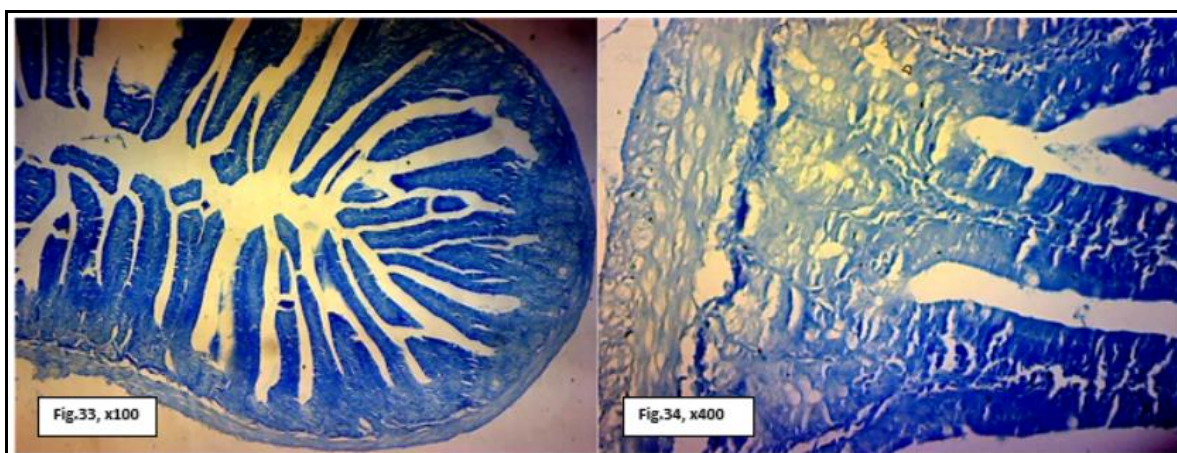
Figs. (27&28): Photomicrographs of ileum of the mice received tramadol (T₁) stained with bromophenol blue showing weak protein content with weak blue stainability.



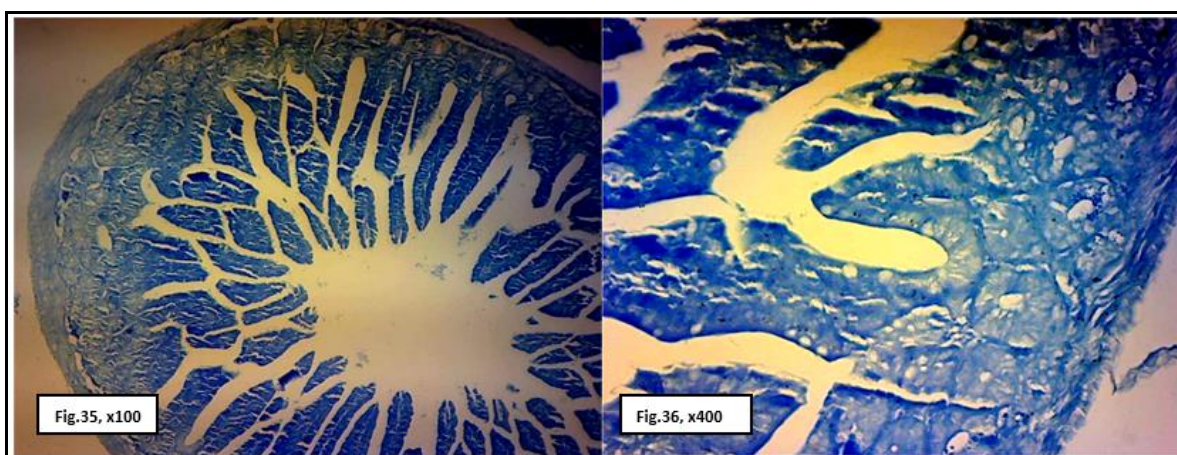
Figs. (29 & 30): Photomicrographs of ileum of the mice received tramadol (T₂) stained with bromophenol blue showing weak protein content with weak blue stainability.



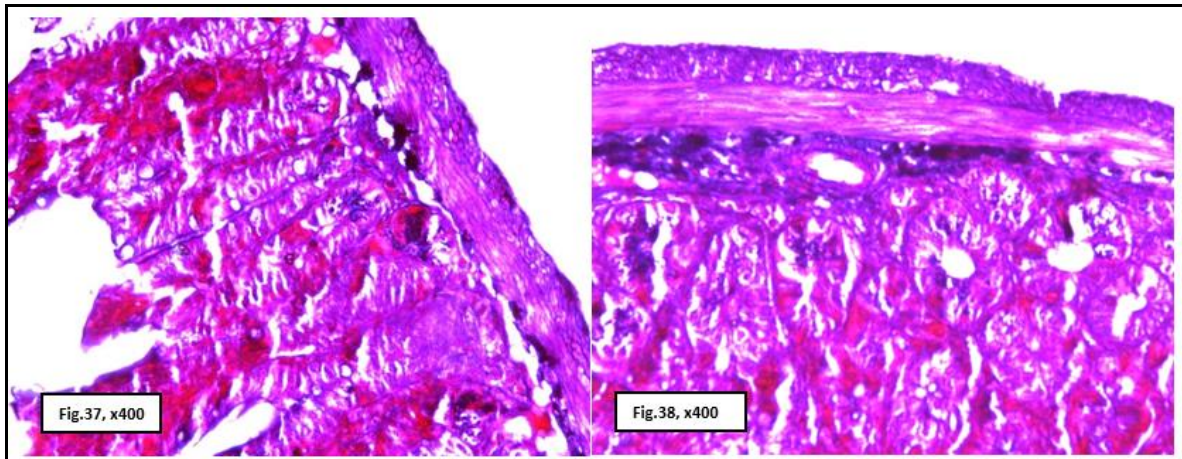
Figs. (31 & 32): Photomicrographs of ileum of the mice after stopping tramadol injection (T_s) stained with bromophenol bleu showing moderately protein content inside cells with moderate blue stainability.



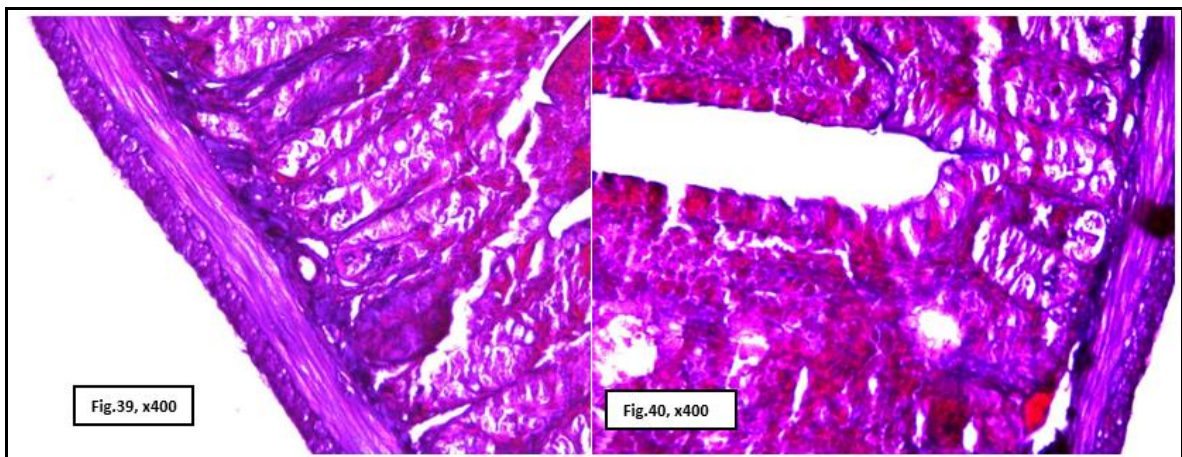
Figs. (33 & 34): Photomicrographs of ileum of the mice received tramadol and *Lagenaria siceraria* (T_L) stained with bromophenol bleu showing moderately protein content with moderate blue stainability.



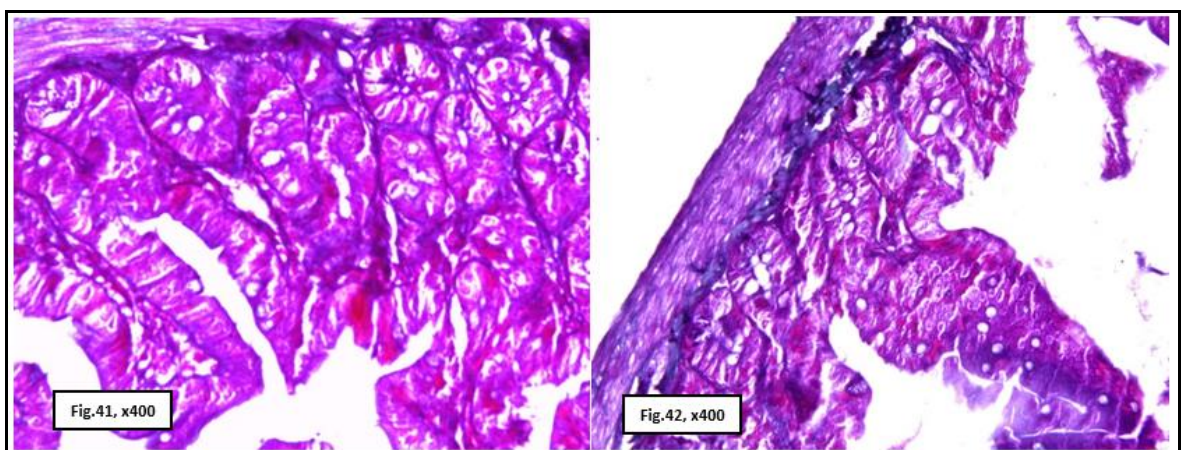
Figs. (35 & 36): Photomicrographs of ileum of the mice received tramadol and melatonin (T_M) stained with bromophenol bleu showing moderately protein content with moderate blue stainability.



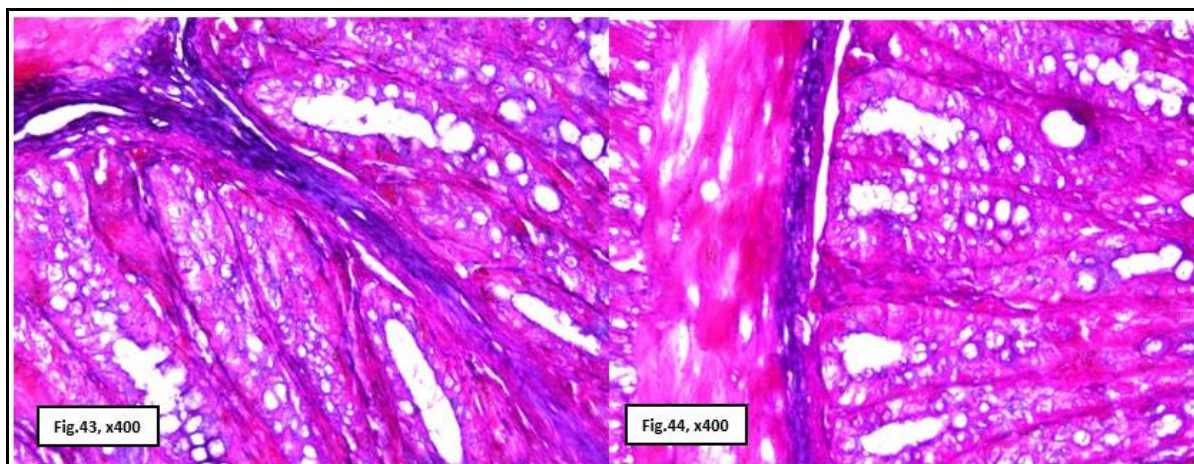
Figs. (37 & 38): Photomicrographs of the ileum of the control mice(C) stained with Mallory trichrome showing normal distribution of collagen fibers.



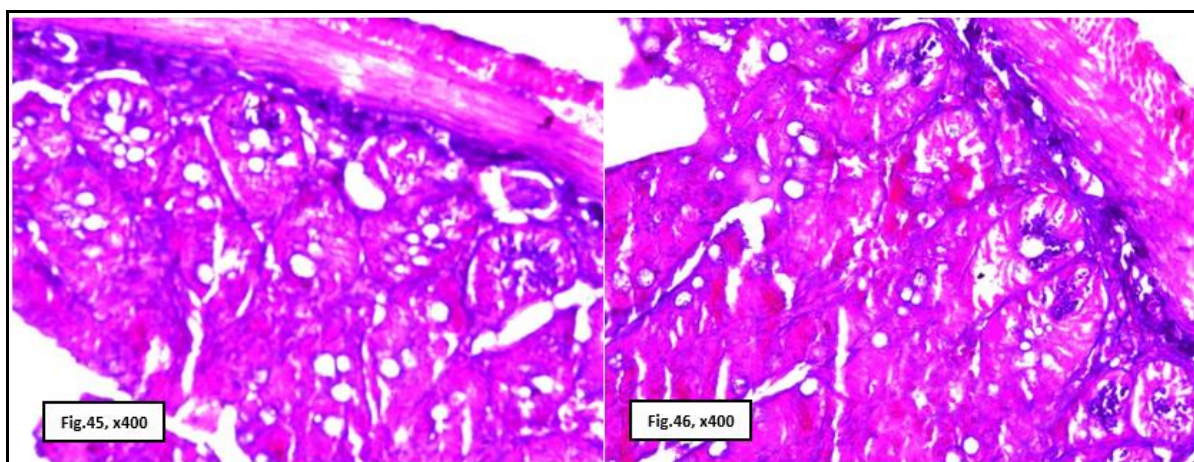
Figs. (39 & 40): Photomicrographs of ileum of the mice received tramadol (T₁) stained with Mallory trichrome showing intense precipitation of deeply stained blue coloration of collagen fibers.



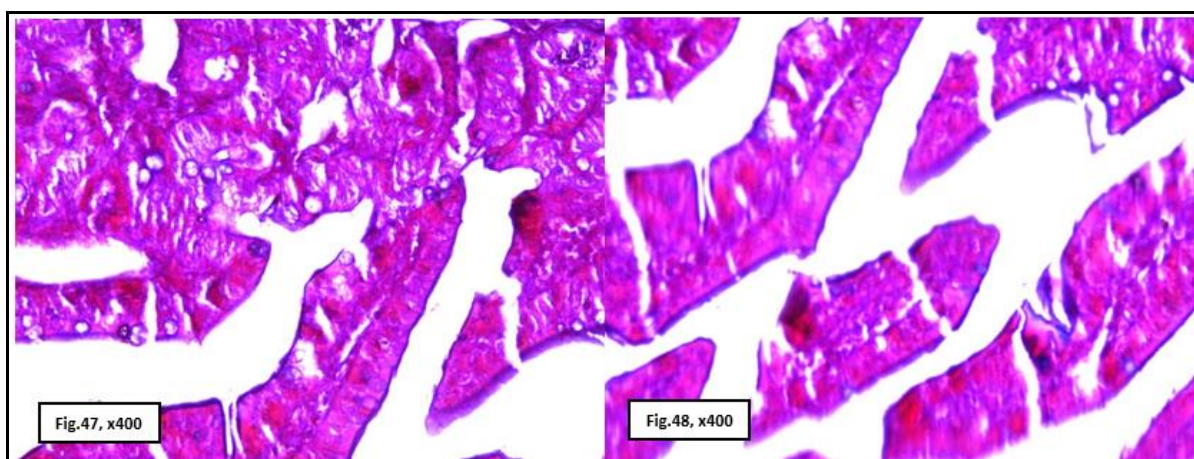
Figs. (41 & 42): Photomicrographs of ileum of the mice received tramadol (T₂) stained with Mallory trichrome showing pronounced fibrosis with intense blue coloration of collagen fibers



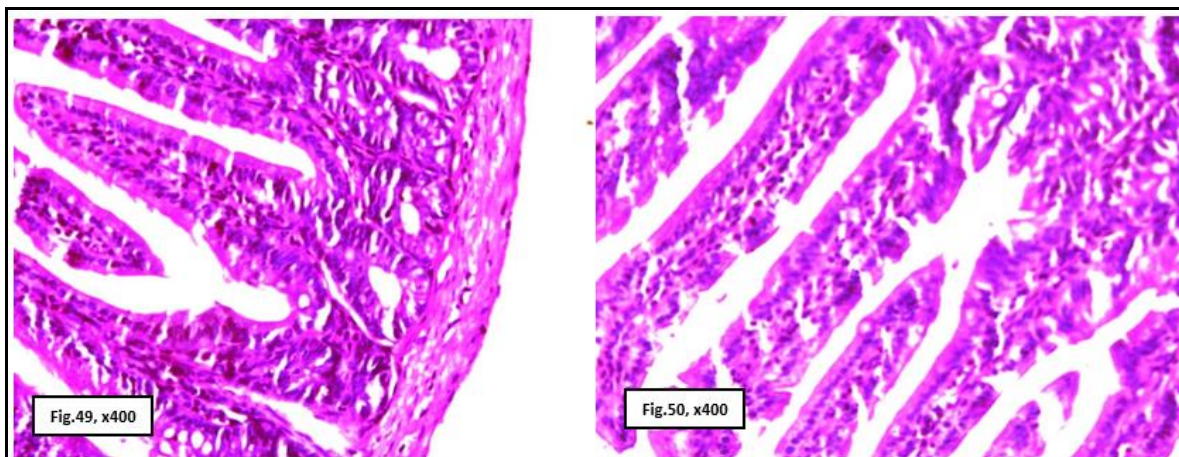
Figs. (43 & 44): Photomicrographs of ileum of the mice after stopping tramadol injection (T_s) stained with Mallory trichrome showing moderately collagen fibers precipitation.



Figs. (45 & 46): Photomicrographs of ileum of the mice received tramadol and *Lagenaria siceraria* (T_L) stained with Mallory trichrome showing minimal collagen fibers precipitation.



Figs. (47 & 48): Photomicrographs of ileum of the mice received tramadol and melatonin (T_M) stained with Mallory trichrome showing slight collagen fibers precipitation.



Figs. (49) Photomicrograph of the ileum of the control mice(C) showing ileum layers involving mucosa, submucosa, muscularis and serosa (**H&E**).

Fig. (50): Photomicrograph of the ileum of the control mice(C) showing ileum villi (**H&E**).

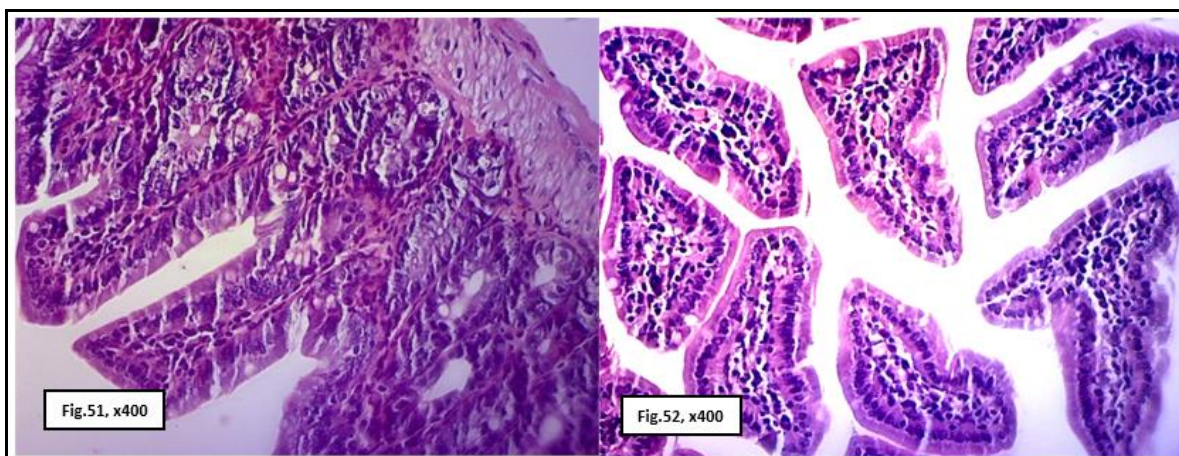


Fig. (51): Photomicrographs of ileum of the mice received tramadol (T_1) showing necrosis and desquamation of the ileum epithelial lining villi (**H&E**).

Fig. (52): Photomicrograph of the same mice (T_1) showing necrosis and lysis of the tips of the ileum villi (**H&E**).

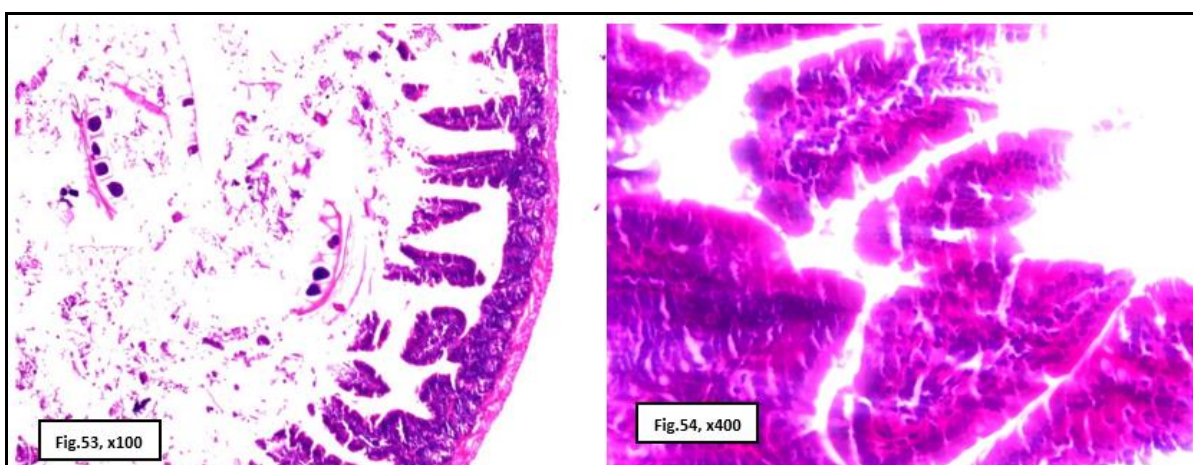
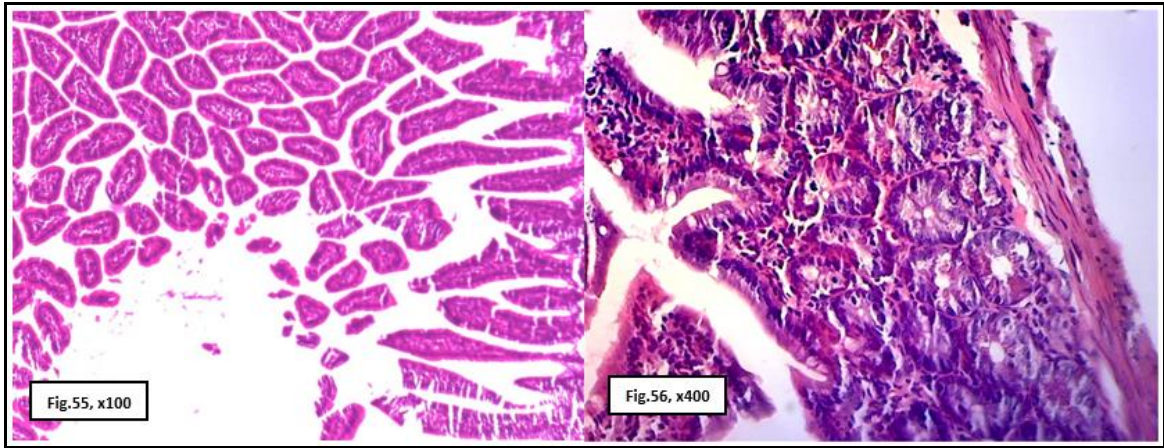


Fig. (53): Photomicrograph of ileum of the mice received tramadol (T_1) showing ileum lumen filled with tissues debris and edematous fluids (**H&E**).

Fig. (54): Photomicrograph of ileum of the mice received tramadol (T_1) showing inflammatory cells infiltration (**H&E**).



Figs. (55 & 56): Photomicrographs of ileum of the mice received tramadol (T_2) showing extensive necrosis and desquamation of the ileum tips (**H&E.**).

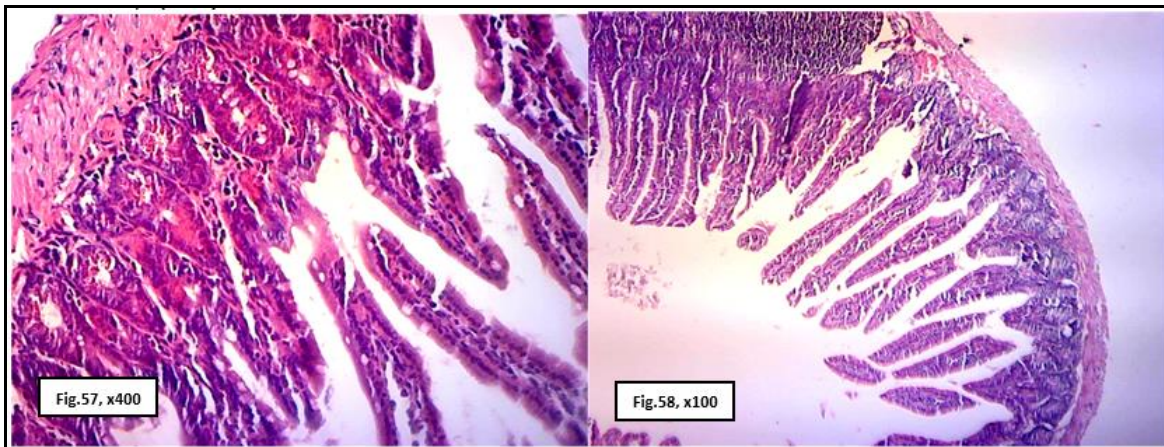


Fig. (57): Photomicrograph of ileum of the mice received tramadol (T_2) showing ileum vacuolation and degeneration (**H&E.**).

Fig. (58): Photomicrograph of ileum of the mice after stopping tramadol injection (T_3) showing congestion of blood vessels (**H&E.**).

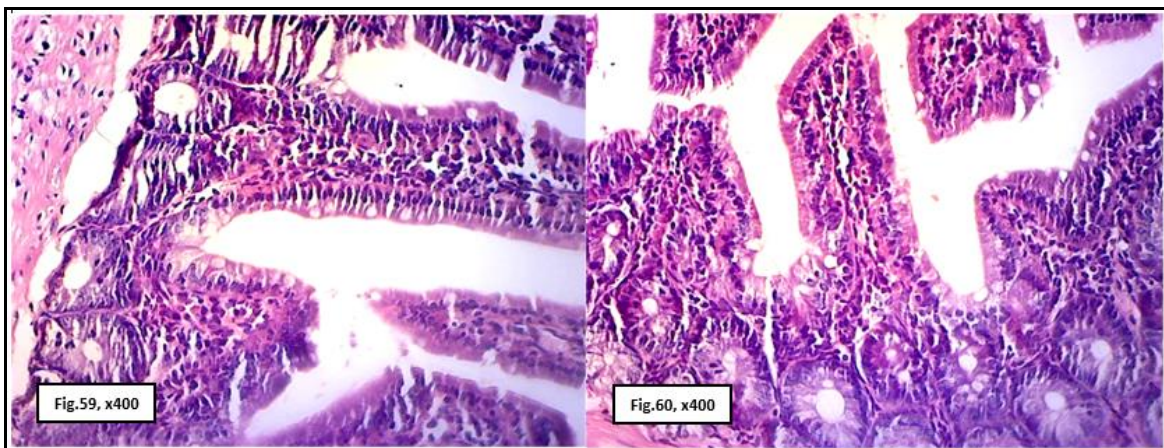
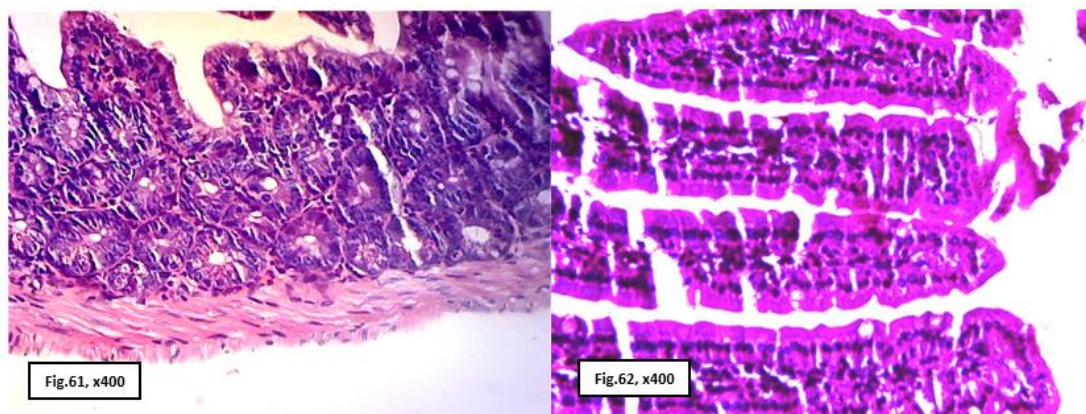


Fig. (59): Photomicrograph of ileum of the mice after stopping tramadol injection (T_3) showing thickening of tunica muscularis with fibrous tissues (**H&E.**).

Fig. (60): Photomicrograph of ileum of mice (T_3) showing desquamation and necrosis of the ileum villi (**H&E.**).



Photomicrographs of ileum of the mice received tramadol and *Lagenaria siceraria* (T_L) showing normal arrangement of the ileum layers **Fig. (61)** and villi **Fig. (62)** (H&E.).

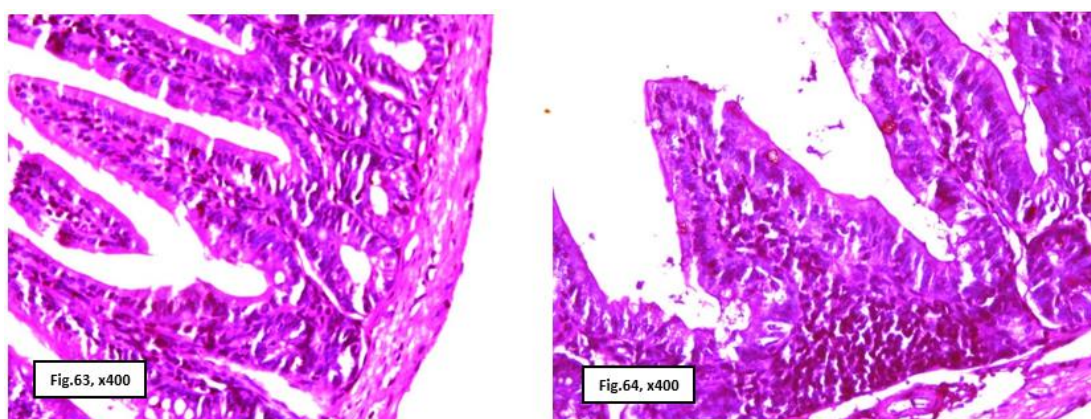


Fig. (63): Photomicrograph of ileum of the mice received tramadol and melatonin (T_M) showing normal ileum layers (H&E.) **Fig. (64):** Photomicrograph of ileum of the mice received tramadol and melatonin (T_M) showing focal inflammatory cells infiltration (H&E.).

DISCUSSION

Oxygen-free radicals produced from tramadol have shown to induce DNA breaks and DNA damage. The appearance or disappearance of protein fraction in the present study may be attributed to this damage or may be explained by the report of Bedwell *et al.* (1989), who claimed that the free radicals promote sulfhydryl mediated cross-linking of the labile amino acids such as methionine, histidine, cysteine and lysine causing a fragmentation of polypeptide chains in the protein molecule. Tramadol increased lipid peroxidation, due to long term use (Atici *et al.*, 2005). In living cells, when the formation of intracellular reactive oxygen species exceeds the cell's antioxidant capacity, oxidative stress can rise resulting in damage to

cellular macromolecules such as proteins, lipids and DNA (Nordberg and Arner, 2001; Valko *et al.*, 2007).

Verma and Kaplowitz. (2009) stated that acetaminophen overdose is currently the most frequent cause of acute liver failure, evaluation of the mechanisms of drug-induced liver injury indicates that mitochondria are critical targets for drug toxicity, either directly or indirectly through the formation of reactive metabolites. The consequence of these modifications is generally a mitochondrial oxidant stress and peroxynitrite formation, which leads to structural alterations of proteins and mitochondrial DNA and, eventually, to the opening of mitochondrial membrane permeability transition (MPT) pores. MPT pore formation results in a collapse of

mitochondrial membrane potential and cessation of adenosine triphosphate synthesis. In addition, the release of intermembrane proteins, such as apoptosis-inducing factor and endonuclease G, and their translocation to the nucleus, leads to nuclear DNA fragmentation.

From the cytological point of view, the present results indicated that the tramadol has continuously inhibitory effect on the nuclei volume of epithelial cells lining villi in ileum of male mice which resaved tramadol for 20 or 40 days.

From the cytological point of view, all previous treatments, stopping tramadol or *Lagenaria siceraria* or melatonin, revealed an inhibitory effect on the changes induced by tramadol on volume nuclei of epithelial cells lining villi in ileum in mice but did not reach to control mice.

Although, Tramadol has an inhibitory effect on cellular activity treatments with stopping tramadol or *Lagenaria siceraria* or melatonin decreased this tramadol effect.

The present work is a part from M.Sc. thesis (Mariam M. Jad *et al.*, In Press), the ileum of animals received tramadol for 40 days and left for a recovery period (40 days). Organs showed partial improvement in the total proteins and nucleic acids materials content versus mice which received tramadol for 40 days and then sacrificed or control mice.

The reduction of protein, nucleic acids and polysaccharides contents in cells of kidney (Mariam M. Jad *et al.*, In Press) and ileum recorded in this work were particularly restored approximately 40 days after the abstinence of tramadol, but such restorations were apparently relatively incomplete compared within mice previously treated for 40 days only. Regarding the possible recovery of investigated chemical materials content in animal kidney and ileum following tramadol drug withdrawal,

no studies seem to have been carried out in this respect.

From the histochemical point of view, the results of the present work indicated that tramadol has similar side effects on chemical component materials (such as protein, nucleic acids) in the epithelial cells lining ileum of male mice. In the present study, the daily administration of mice with the therapeutic dose of tramadol for 20 days or 40 days caused a remarkable reduction in the total proteins contents of investigated cells of the ileum to compare with those of the control mice. The reduction of protein content observed in this study may be attributed partially to the decrease of hepatic protein synthesis due to the hyperactivity of hydrolytic enzymes (Sivaprasada *et al.*, 1983). Furthermore, this decrease in protein content can be explained by Chen *et al.* (1999), who stated that initiation of lipid peroxidation, necrosis and subsequent impairment in cellular metabolism collectively altered the major cellular components, including protein, and glycogen.

Experimental studies have also supported the toxic effects of chronic use of opioids on liver proteins. Hashiguchi *et al.* (1996) studied the central effects of morphine and morphine-6-glucuronide on tissue protein synthesis. They found that morphine and M6G suppress tissue protein synthesis through central mechanisms, mediated by opiate-induced respiratory

In the present study, the daily administration of mice with the therapeutic dose of tramadol for 20 days or 40 days caused a remarkable increase of collagen content in investigated cells of kidney and ileum to compare with those of control mice. These results may be interpreted as a secondary event following tramadol-induced lipid peroxidation of renal tissues. Lipid peroxidation of cell membranes leads to loss of membrane fluidity, changes in membrane

potential and an increase in membrane permeability, all of which lead to alteration of the chemical compound of the cells. The increased collagen fibers occur due to decreased collagen metabolism that may be related to oxidative stress (Altindag *et al.*, 2008).

Despite, the beneficial reduction in Myeloperoxidase (MPO) activity caused by the opioid agents, in the current study, there was no corresponding decrease in histological verify score. However, tramadol as the most efficacious agent in reducing MPO, showed a trend toward restoration of villus height. It is noteworthy that this effect also occurred in healthy animals and is previously unreported. In order to fully understand the inflammatory processes occurring in chemotherapy-induced mucositis, their relation to histological repair and synergism between therapeutics, future studies should investigate inflammatory markers such as the pro-inflammatory cytokines and cyclooxygenase activity. Mechanisms of pain production by cytotoxic agents in gastrointestinal mucositis are poorly understood, (Cata *et al.*, 2008). Yet pain remains one of the key dose-limiting factors for patients (Gibson *et al.*, 2015). However, research effort in this area is likely to increase since the discovery that: 1) chemotherapy-related hyperalgesia can be reversed by immune-modulatory agents (Gibson *et al.*, 2015) and there is a high level of μ -opioid receptor expression in the intestinal tract, particularly during inflammation (Philippe *et al.*, 2003).

Therefore, the ability to reliably measure affective pain as opposed to nociception is a much-needed animal model refinement. This study has indicated that behavioral pain assessment scoring may be one such tool but does require further validation. The present data do however raise some concerns with the ability of the model to replicate the human mucositis condition if human patients frequently

require morphine omimetic agents to control pain

Opioids are the most potent and effective analgesics available and have become accepted as an appropriate treatment for acute or cancer and non-cancer chronic pain (Collet, 2001). However, they are also rewarding and their repeated use can lead to dependence and addiction. In fact, addiction to opioid analgesics is a growing socioeconomic and health problem with potentially serious consequences documented by a rise in deaths due to overdose (Hall *et al.*, 2008).

In the present work, in ileum, tramadol showed necrosis and desquamation of the intestinal villi, intestinal vacuolation and degeneration, and congestion of blood vessels. Tramadol administration induced histopathological side effects on the architecture of ileum in mice such as extensive necrosis, desquamation of the intestinal tips, ileum vacuolation, and degeneration. Similar results are reported by Whittaker *et al.* (2016).

Oxidative stress-induced by opiate exposure is a significant factor in the etiology of male infertility and can lead to increased DNA fragmentation (Lamont and Mathews, 2007). Also, Vuong *et al.* (2010) found that tramadol enhance testicular levels of nitric oxide and lipid peroxidation and decreased the activities of the antioxidant enzymes significantly compared with control.

Our results indicated that the daily injection of tramadol for 20 or 40 days decreased markedly DNA materials content in epithelial cells of renal tubules in kidney and lining epithelial cells of villi of ileum of mice versus control. These results may be attributed to the damage of DNA report Bedwell *et al.* (1989) and Vuong *et al.* (2010) described that tramadol decreases the activities of the antioxidant enzymes significantly. Also, oxidative stress induced by

opiate exposure is a significant factor can lead to increased DNA fragmentation (Lamont and Mathews, 2007).

On the contrary, the administration of *Lagenaria siceraria* diminished and alleviated the pathological changes.

Since kidney showed slight degree of necrosis and degeneration with slight congestion in blood vessels, also, minimally mononuclear infiltration was detected. Ileum exhibited normal arrangement of the intestinal layers and villi.

Lagenaria siceraria showed minimal collagen fibers distribution in kidney and ileum. Also by PAS and bromophenol techniques, kidneys and ileum showed high polysaccharides and protein contents with deeply stained red and blue color, respectively.

Ghosh *et al.* (2009) displayed the antioxidant potential of *Lagenaria siceraria* which accounts for cytotoxic activity. *Lagenaria siceraria* fruits contain a water-soluble polysaccharide, which is composed of 3-O-acetyl methyl- α -D-galacturonate, methyl- α -D-galacturonate, and α -D-galactose in a ratio of 1:1:1. The polysaccharide possesses cytotoxic activity in vitro. Also, *Lagenaria siceraria* has radical scavenging activity (Deshpande *et al.*, 2009). *Lagenaria siceraria* offered immunomodulatory effects of n-butanol soluble and ethyl acetate soluble fraction of the successive methanol extract of *Lagenaria siceraria* (Gangwal *et al.*, 2008). So *Lagenaria siceraria* could reverse changes in the tissues.

Moreover, the administration of melatonin corrected and ameliorated the pathological changes induced by tramadol. The kidney showed slight necrosis and degenerative changes with sloughing in some renal epithelium, while other renal tubules detected regeneration and mild congestion of the blood vessels. Also, a mild degree of fibrous tissue

infiltration was observed. Ileum demonstrated intestinal layers with some inflammatory cell infiltration.

Melatonin functions in scavenging free radicals might be classified in to four main categories: (1) as an antioxidant directly scavenges ROS (Reiter, 2000), (2) in stimulating the antioxidant enzymes production and activation (Rodriguez *et al.*, 2004) and (3) in increasing the efficacy of mitochondrial functions by improving MPTP, inhibition of cytochrome c release and refining of oxidative phosphorylation in mitochondrial respiratory chain which further will decrease the peroxidation of membrane lipids (Acuna-Castroviejo *et al.*, 2007).

Moreover, Permpoonputtana and Govitrapong (2013) revealed that the anti-neuroinflammatory effects of melatonin resulted from the inhibition of activated NF- κ B in a cell signaling pathway. Melatonin as pre-treatment can reduce pro-inflammatory cytokines IL-1 β and TNF- α and increases the serum levels of anti-inflammatory cytokine IL-4 (Carrasco *et al.*, 2013). These results are consistent with the findings of acetic acid-Induced Colitis in rats. Melatonin completely improves the latter inflammation (Tahan *et al.*, 2011). Melatonin inhibits peroxy-nitrite production and activation of poly ADP ribosesynthetase (nuclear enzyme) in macrophages of rats exposed to zymosan-induced shock (Maestroni, 1993). Inhibition of peroxy-nitrite production by melatonin due to anti-inflammatory effects (Poeggeler *et al.*, 1993).

Finally, we could say, from the cytological, histochemical and histopathological point of view, the present data showed tramadol administration for 20 or 40 days decreased the nuclei volume and cellular chemical contents; DNA, RNA and protein of epithelial cells lining villi in ileum of male mice. Thus, tramadol adversely affects cellular activities, including cell division and

protein synthesis, which are finally reflected in histopathological changes. Although, Tramadol has inhibitory effect on cellular activity but

REFERENCES

- Acuna-Castroviejo, D.; Escames, G.; Rodriguez, M. I. and Lopez, L. C. (2007): Melatonin role in the mitochondrial function. *Front. Biosci.*, 12: 947-963.
- Altindag, O.; Erel, O.; Soran, N.; Celik, H. and Selek, S. (2008): Total oxidative/anti-oxidative status and relation to bone mineral density in osteoporosis. *Rheumatol. Int.*, 28: 317–21.
- Aslam, M. and Najam, R. (2013): A review of pharmacognostical, phytochemical and pharmacological properties of *Lagenaria siceraria*: A miracle herb. *International Journal of Biomedical and Advance Research*, 04 (05): 266-274. ISSN: 2229-3809.
- Atici, S.; Cinel, I.; Cinel, L.; Doruk, N. and Eskandari, G., U. (2005): Liver and Kidney Toxicity in Chronic Use of Opioids: An Experimental Long Term Treatment Models. *Journal of Biosciences*. 30 (2): 245-252.
- Bedwell, S.; Dean, T. and Jessup, W. (1989): The action of defined oxygen-centred free radicals on human low-density lipoprotein. *Biochem. J.*, 262: 707– 712.
- Bohnert, A.S.; Valenstein, M. and Bair, M.J. (2011): Association between opioid prescribing patterns and opioid overdose-related deaths. *J.A.M.A.*, 305:1315–1321.
- Cao, R.; Jia, J.; Ma, X.; Zhou, M. and Fei, H. (2013): Membrane localized iridium (III) complex induces endoplasmic reticulum stress and mitochondria-mediated apoptosis in human cancer cells. *J. Med. Chem.*, 56 (9): 3636-3644.
- treatments with stopping tramadol administration or *Lagenaria siceraria* or melatonin decreased this tramadol effect.
- Carleton, H. M.; Drury, R. A. B. and Wallington, E. A. (1980). Carleton's histological technique. Oxford University Press, USA.
- Carrasco, C.; Marchena, A. M.; Holguín-Arévalo, M. S.; Gervasio Martín-Partido, and Ana B. Rodríguez; et al. (2013): Anti-inflammatory effects of melatonin in a rat model of caerulein-induced acute pancreatitis. *Cell Biochem. Func.*, 31 (7): 585-590.
- Carrillo-Vico A; Guerrero J. M.; Lardone, P.J. and Reiter R. J. (2005): A review of the multiple action of melatonin on the immune system. *Endocrine*. 27 (2):189-200.doi:10.1385/endo:27:2:189.
- Cata, J. P.; Weng, H-R.; Dougherty, P. M. (2008): The effects of thalidomide and minocycline on axol-induced hyperalgesia in rats. *Brain. Res.*, 1229: 100–10. doi:10.1016/j.brainres.07.001PMID: 18652810 51.
- Chen, W.; Shockcor, J. P.; Tonger, R.; Hunter, A.; Gartner, C. and Nelson, S. D. (1999): Protein and nonprotein cysteinylthiol modification by N-acetyl- p benzoquinoneimine via a novel ipso adduct. *Biochemistry*. 38: 8159.
- Collet, B. J. (2001): Chronic Opioid Therapy for Non-Cancer Pain. *Br. J. Anaesth.* 87: 133-143.
- Deshpande, S.; Basil, M. D. and Basil, D. Z. (2009): Factors influencing healthy eating habits among college students: An application of the health belief model. *Health marketing quarterly*. 26 (2): 145-164.
- Gangwal, A.; Parmar, S. K.; Gupta, G. L., Rana, A. C. and Sheth, N.

- R. (2008): Immunomodulatory effects of *Lagenaria siceraria* fruits in rats. *Pharmacog Mag.* 2008; 4 (16): 234 -238.
- Ghosh, K.; Chandra, K.; Ojha A.K.; Sarkar, S. and Islam, S.S. (2009): Structural identification and cytotoxic activity of a polysaccharide from the fruits of *Lagenaria siceraria*. *Carbohyd Res.* 344 (5): 693-698.
- Gibson, R. J.; Coller, J. K.; Wardill, H. R.; Hutchinson, M. R.; Smid, S. and Bowen, J. M. (2015): Chemotherapy induced guttoxicity and pain :involvement of TLRs. *Support Care Cancer.* doi :10.1007/s00520-015-3020-2 52.
- Hall, A. J.; et al. (2008): Patterns of abuse among unintentional pharmaceutical overdose fatalities. *J.A.M.A.* 300: 2613-2620.
- Hashiguchi, Y.; Molina, P. E.; Preedy, V. R.; Sugden, P. H.; McNurlan, M. A.; Garlick, P. Jm.; Avmar, N. N. (1996): Central effects of morphine and morphine-6-glucuronide on tissue protein synthesis. *Am. J. Physiol.*, 271 (3): R619–R625.
- Holden, J. E.; Jeong, Y. and Forrest, J. M. (2005): The endogenous opioid system and clinical pain management. *A.A.C.N. Clin. Issues*; 16: 291- 301.
- Kumer, K. A.; Naidu M. U.; Shifow A. A. and Prayag A. (1999): Ratnakar KS.Melatonin: an antioxidantprotects against cyclosporine-indduced nephropathy. *Transplantation.* 199904, 67(7):1065-8.doi:10.1097/00007890-04150-00022.
- Lamont, L. A. and Mathews, K. A. (2007): Opioids, Nonsteroidal Anti-Inflammatories, and Analgesic Adjuvants, in Lumb and Jones. *Veterinary Anesthesia and Analgesia*, Blackwell Publishing. 4: 241-272.
- Lewiński, A.; Vaughan, M. K.; Champney, T. H.; Reiter, R. J. and Smith, N. K. R. (1984): Inhibitory action of the pineal gland on nuclear volume of thyroid follicular cells in mail gerbils. *Exp. Clin Endocrinol.* 84 (2): 239-244.
- Maestroni, G. J. (1993): The immunoneuroendocrine role of melatonin. *J. Pineal. Res.* 14 (1): 1-10.
- Mariam M. Jad, Abdel-baset M. Aref, Hoda S. Mohamedain, and Margit Semmler (2018): Effects of *lagenaria siceraria* and melatonin on tramadol-induced changes in some organs of mice: cytological and histochemical studies. M.Sc. thesis, Zoology Department, faculty of sciences, South valley university, Kena, Egypt. In Press.
- Moore, K. A.; Cina, S. J.; Jones, R.; Selby, D. M.; Levine, B. and Smith, M. L. (1999): Tissue distribution of tramadol and metabolites in an overdose fatality. *Am. J. Forensic Med. Pathol.*, 20 (1): 98-100.
- Nordberg J and Arner E S. (2001): Reactive oxygen species, antioxidants and the mammalian thioredoxin system. *Free Radic Biol Med.*, 31: 12871312.
- Okie, S. (2010). Reviving the FDA. *New England journal of medicine.* 363 (16): 1492-1494.
- Pearse, A. (1980). *Seeds of Plenty, Seeds of Want: Social and Economic Implications of the Green Revolution.* Revisiting Sustainable Development. 139.
- Permpoonputtana, K. and Govitrapong, P. (2013): The anti-inflammatory effect of melatonin on methamphetamine-induced proinflammatory mediators in

- human neuroblastoma dopamine sh-sy5y cell lines. *Neurotox. Res.*, 23 (2): 189-199 (2013).
- Philippe, D.; Dubuquoy, L.; Groux, H.; Brun, V.; Chuoi-Mariot, M. T. V.; Gaveriaux-Ruff, C.; et al. (2003): Antiinflammatory properties of the μ opioid receptor support its use in the treatment of colon inflammation. *J. Clin. Invest.* 111 (9): 1329–38. PMID: 12727924.
- Poeggeler, B.; Saarela, S.; Reiter, R. J.; Tan, D. X. and Chen, L.D. (1993): Melatonin--a highly potent endogenous radical scavenger and electron donor: new aspects of the oxidation chemistry of this indole accessed in vitro. *Ann. NY. Acad. Sci.* 1: 57-60.
- Pypendop, B. H. and Ilkiw, J. E. (2008): Pharmacokinetics of tramadol, and its metabolite o-desmethyl-tramadol, in cats. *J. Vet. Pharmacol. Ther.*, 31: 52-59.
- Reiter, R. J. (1998): Oxidative damage in the central nervous system: protection by melatonin. *Progress in neurobiology.* 56 (3): 359-384.
- Reiter, R. J. (2000): Melatonin: Lowering the High Price of Free Radicals. *News. Physiol. Sci.* 15(5), 246-250.
- Reiter, R. J.; Calvo, J. R.; Karbownik, M.; Qi, W. and Tan, D.X. (2000): Melatonin and its relation to the immune system and inflammation. *Ann. N.Y. Acad. Sci.*, 917: 376–386.
- Rodriguez, C.; Mayo, J. C.; Sainz, R. M.; Antoli-n, I. and Herrera, F.; et al. (2004): Regulation of antioxidant enzymes: a significant role for melatonin. *J. Pineal. Res.* 36(1), 1-9.
- Seddighi, M. R.; Egger, C. M.; Rohrbach, B.W.; Cox, S. K. and Doherty, T. J. (2009): Effects of tramadol on the minimum alveolar concentration of sevoflurane in dogs. *Vet. Anaesth. Analg.*, 36: 334-340.
- Shadnia, S.; Soltaninejad, K.; Heydari, K.; Sasanian, G. and Abdollahi M. (2008): Tramadol intoxication: a review of 114 cases. *Hum. Exp. Toxicol.*, 27: 201-205.
- Sivaprasada, K.; Sombasiva, K. R. and Ramana, K. V. (1983): Effect of parathion on tissue ionic changes fish channa punctatus Geobios. *Jodhpur.* 10: 60-62.
- Tahan, G.; Gramignoli, R.; Marongiu, F.; Aktolga, S. and Cetinkaya, A.; et al. (2011): Melatonin Expresses Powerful Anti-inflammatory and Antioxidant Activities Resulting in Complete Improvement of Acetic-Acid-Induced Colitis in Rats. *Dig. Dis. Sci.* 56(3), 715-720 (2011).
- Tjäderborn, M.; Jönsson, A. K.; Hägg, S. and Ahlner, J. (2007): Fatal unintentional intoxications with tramadol during. *Forensic Sci. Int.*, 173: 10711.
- Valko, M.; Leibfritz, D.; Moncol, J.; Cronin, M. T.; Mazur, M. and Telser, J. (2007): Free radicals and antioxidants in normal physiological functions and human disease. *Int. J. Biochem Cell Biol.*, 39(1): 44-84.
- Verma, S. and Kaplowitz, N. (2009): Diagnosis, management and prevention of drug-induced liver injury. *Gut.* 58 (11):1555-64.
- Vuong, C.; Van Uum, S. H.; O'Dell, L. E.; Lutfy, K. and Friedman, T. C. (2010): The Effects of Opioids and Opioid Analogs on Animal and Human Endocrine Systems [Review]. *Endocrine Reviews Journals.* 31 (1): 98-132.
- Vuong, C.; Van Uum, S. H.; O'Dell, L. E.; Lutfy, K. and Friedman, T.

- C. (2010): The Effects of Opioids and Opioid Analogs on Animal and Human Endocrine Systems [Review]. *Endocrine Reviews Journals*. 31 (1): 98-132.
- Whittaker, A. L.; Lymn, K. A.; Wallace, G. L. and Howarth, G.
- S. (2016): Differential Effectiveness of Clinically-Relevant Analgesics in a Rat Model of Chemotherapy-Induced Mucositis. *PLoS ONE* 11 (7): e0158851. doi: 10.1371/journal.pone.0158851.